

# Disorganization of Retinal Inner Layers in Diabetic Patients

Nimra Akram<sup>1</sup>, Mazhar Ul Hassan<sup>1</sup>

## Abstract:

**Objective:** To investigate the prevalence of Disorganization of Retinal Inner Layers (DRIL) in patients with diabetes and its relationship with Diabetic Macular Edema (DME) and initial visual acuity.

**Methods:** This cross-sectional study involved 96 patients aged between 30-70 years with diabetes who underwent spectral-domain optical coherence tomography (SD-OCT) scans to evaluate Disorganization of Retinal Inner Layers (DRIL) and Diabetic Macular Edema (DME). Data were entered and analyzed using SPSS version 23.

**Results:** Out of 96 patients, 46 (47.9%) were males and 50 (52.1%) were females. Diabetic Macular Edema (DME) was found in 60 (62.5%) patients. There was a significant association between the existence of diabetic macular edema and DRIL. The findings revealed that DRIL was present in 44.8% of patients and was significantly linked to central foveal thickness and visual acuity.

**Conclusion:** The study suggests that DRIL is a valuable indicator for predicting visual outcomes in patients with DME. The presence and extent of DRIL may also have prognostic implications, helping clinicians to identify patients who are at higher risk of vision loss. *Al-Shifa Journal of Ophthalmology* 2025; 21(2): 113-. © Al-Shifa Trust Eye Hospital, Rawalpindi, Pakistan.

1. Dow Medical College and Dr. Ruth  
K.M Pfau Civil Hospital, Karachi.

Originally Received: 05 Feb 2025

Revised: 27 Feb 2025

Accepted: 3 March 2025

## Correspondence to:

Nimra Akram

Dow Medical College and Dr. Ruth K.M.  
Pfau Civil Hospital, Karachi.

nimra2796@gmail.com

## Introduction:

Diabetes mellitus is a global epidemic with profound effects on the retinal microvasculature. Diabetic macular edema is characterized by the buildup of fluid within the retina (intraretinal) and beneath the retina (subretinal), as a consequence of failure of the blood retinal barrier, leading to swelling and thickening of the macula. It is the leading cause of visual impairment in diabetic retinopathy. Diabetic macular edema (DME) is a complex condition that develops due to a combination of factors, including chronically elevated blood sugar levels, damage to the vascular endothelium, and a disrupted balance of growth factors and cytokines. Over time, chronic edema can lead to permanent structural changes, including: Disruption of the retinal layers, cystoid spaces, retinal fibrosis, and vision loss<sup>1, 2</sup>.

The Early Treatment Diabetic Retinopathy Study (ETDRS) identified central retinal thickness, via slit lamp biomicroscopy and Color fundus photographs, as potential markers to guide treatment for diabetic macular edema. However, small changes in

retinal thickness cannot be assessed via these methods due to their subjective nature. The problem was partially resolved by the subsequent availability of time-domain optical coherence tomography (OCT) as it precisely quantified the overall retinal thickness, but later studies suggested that, although overall retinal thickness is related to visual acuity, it is only to a moderate extent<sup>3</sup>.

The commencement of landmark investigation in ophthalmology, spectral-domain OCT (SD-OCT), enabled the production of high-resolution images of retinal layers and hence improved the ability to detect retinal pathology in individual layers. Previous research has reliably predicted two of the SD-OCT biomarkers, the intactness of the external limiting membrane (ELM) and ellipsoid zone (EZ), to be consistently related to visual acuity in diabetic macular edema<sup>4</sup>.

In 2014, Sun et al were the first to identify disorganization of the retinal inner layers (DRIL) as a potential SD-OCT biomarker to be related to visual acuity, such that changing the former predicted changes in the latter. Disorganized Retinal Inner Layers (DRIL) refers to the width (in micrometers) of the area where the normally distinct boundaries between three key retinal layers - the ganglion cell layer-inner plexiform layer (GCL-IPL) complex, inner nuclear layer (INL), and outer plexiform layer (OPL) - become indistinct and cannot be identified on Spectral-Domain Optical Coherence Tomography (SD-OCT) scans. Disorganization of the retinal inner layers (DRIL) is a characteristic feature of various retinal diseases, including diabetic macular edema (DME), retinal vein occlusion, and age-related macular degeneration. The pathogenesis of DRIL involves a complex interplay of factors, including cytotoxic edema, neurodegeneration, Müller cell (the primary glial cells of the retina) dysfunction, release of pro-inflammatory cytokines, ischemia culminating in tissue hypoxia, increased permeability of retinal

vessels, and retinal layer remodeling. These factors contribute to the disorganization of the inner retinal layers, characterized by: Loss of clear layer boundaries, Cell death and migration, Axonal disruption, and Synaptic loss<sup>1</sup>. Another observational case series demonstrated that the presence of DRIL exaggerated diabetic retinopathy<sup>5</sup>. In a recent study, patients who had non-proliferative diabetic retinopathy and naïve center-involved diabetic macular edema were studied for the presence of DRIL, and the frequency of DRIL turned out to be 52.63%<sup>6</sup>. Another cross-sectional study investigated the impact of DEX (dexamethasone) implant on DRIL in DME. They reported the frequency of DRIL at baseline to be 52.5% and regarded it as a negative prognostic factor<sup>7</sup>. DRIL can lead to significant visual impairment, as the inner retinal layers play a critical role in transmitting visual information from the photoreceptors to the brain. Santos et al. in their study demonstrated DRIL as a predictor of poor visual outcome after treatment with anti-VEGF (vascular endothelial growth factor) therapy for diabetic macular edema<sup>8</sup>. Furthermore, after diabetic macular edema subsides, the resolution pattern of DRIL predicts the visual acuity<sup>9</sup>. Another study revealed that every 100µm increase in DRIL corresponds to a decline of approximately 6 letters in ETDRS score<sup>5</sup>.

There is no study to date on the frequency of DRIL in DME and its association with BCVA in our population. Furthermore, the significance of identifying this baseline OCT biomarker in diabetic macular edema cannot be neglected, as it will help in gaining better insight into disease management. It will also provide a direction to further longitudinal studies and clinical trials in this area that may explore the response of diabetic macular edema with DRIL to conventional management options. This study aimed to enhance our understanding of retinal layer disruption (DRIL) in treatment-naïve patients, focusing on its early detection and

relationship with best-corrected visual acuity (BCVA). Furthermore, we also sought to determine if any direct association exists between the length of DRIL and central foveal thickness.

To determine the frequency of Disorganization of Retinal Inner layers (DRIL) in Diabetic patients and its association with diabetic macular edema (DME) and baseline best corrected visual acuity.

### **Methodology:**

This study employed an observational cross-sectional design, featuring prospective enrollment of participants. The study was conducted in the Department of Ophthalmology Unit II, Dr Ruth K.M Pfau, Civil Hospital, Dow University of Health Sciences, Karachi. With the help of WHO sample size calculator, taking statistics for the frequency of DRIL as 52.63%<sup>6</sup>, confidence interval 95%, and margin of error as 10%, the sample size calculated was 96. After getting approval from the institute's Ethical Review Board, the study was conducted from May 2024 to October 2024. Patients presenting in the OPD were enrolled in the study after giving informed written consent. Patients aged between 30-70 years, having Type 1 or Type 2 DM, were included in study. While patients having cataract or any other significant media opacity, who had cataract or any other surgery done within past 6 months, administered Intravitreal anti-VEGF agents and Intravitreal steroid therapy, were excluded from study.

Patients were divided into four groups based on their best corrected visual acuity, as follows:

No visual loss (6/6-6/9): 42 (44.8%)

Mild visual loss (6/12-6/18): 27 (28.1%)

Moderate Visual loss (6/24-6/36): 14 (14.6%)

Severe visual loss (6/60 or less): 12 (12.5%)

Questionnaires were filled out by asking questions in the local language. Variables, including demographics, duration of presentation, and type of diabetes, were

noted on a predesigned questionnaire. A comprehensive ophthalmic evaluation was conducted on all patients, consisting of a thorough medical history and a series of diagnostic tests. Visual acuity was assessed using the Snellen chart, while intraocular pressure was measured through applanation tonometry. Confrontation visual field testing and pupillary reaction assessment were also performed to evaluate peripheral vision and neurological function. Additionally, extraocular movements were evaluated to assess eye alignment and motility. A slit lamp examination was conducted to scrutinize the anterior segment, including the cornea, iris, and lens, as well as the posterior segment, comprising the vitreous and retina. Finally, a fundus examination was performed using indirect ophthalmoscopy to provide a detailed view of the retina and its blood vessels. Spectral-domain OCT was performed on all patients enrolled in the study after taking consent and explaining the procedure. All the OCT scans of enrolled patients were performed by a single senior technician. All the scans, including 3D macula and 5-line cross report, were scrutinized for diabetic macular edema and DRIL. Central foveal thickness, within the 1mm zone centered on the fovea, in micrometers, and horizontal extent of DRIL in micrometers were also recorded for each patient. Several scans with DRIL were also recorded for each patient. Central thickness was analyzed using the classical 6\*6mm 3D macula report. In addition to central thickness, it also presents macular thickness and total volume on the ETDRS grid. DRIL was assessed using 5 horizontal B-scans (two scans above and below the foveal scan line) by two retinal specialists independently. In case of any disagreement between the two, the case was discussed between them until a final consensus was reached. The horizontal extent of DRIL was measured in each scan through a software caliper, and global DRIL was calculated by taking the average measurement of all five scans.

Data were entered and analyzed using SPSS version 23. For quantitative variables, normality was assessed by Shapiro Wilk test. Mean and standard deviation/median and interquartile ranges were computed for age, central foveal thickness, and horizontal extent of DRIL. Frequency and percentages were computed for gender, the type of diabetes, therapy used, and presence and/or absence of DRIL. P-value less than or equal to 0.05 was taken as significant. The confidence interval was taken as 95%.

### Results:

The study examined 96 eyes from 96 patients suffering from diabetes mellitus. Of these, 46 (47.9%) were males and 50 (52.1%) were females. 19 (19.8%) patients had Type 1 diabetes, and 77 (80.2%) patients had Type 2 diabetes. The mean age of participants was  $59.2 \pm 9.47$ . 51 (53.1%) patients were using oral hypoglycemic for managing blood sugar levels, 19 (19.8%) were using insulin, while 26 (27.1%) were using both oral hypoglycemic and insulin.

The mean central foveal thickness of the patients in the study was  $296.53 \pm 123.43$ . DRIL was identified in 43 (44.8%) patients (Figure 1). The mean of the horizontal extent of DRIL in these patients was  $352.18 \mu\text{m} \pm 147.91$ . Similarly, the presence of DRIL was not affected by gender ( $p = 0.871$ ). The type of therapy (oral hypoglycemic, insulin and oral hypoglycemic combined with insulin) had no significant association with the occurrence of DRIL ( $p = 0.130$ ). There was no correlation between the age of the patient and horizontal extent of DRIL in micrometers ( $p = 0.351$ ). However, it was found that type 1 diabetics had statistically lower horizontal extent of DRIL ( $234.28 \mu\text{m}$ ) than type 2 diabetics ( $375.11 \mu\text{m}$ ), a mean difference of  $140.82 \mu\text{m}$  (95% CI, 24.09 to 257.55),  $t(41) = 2.43$ ,  $p = 0.019$ . Moreover, it was also revealed that patients who developed DRIL had a longer duration of diabetes (17 years) than those who hadn't (4.5 years), a mean difference of 12.46 years (95% CI, 10.59 to 14.33),  $t(94) = 13.21$ ,  $p < 0.001$ .

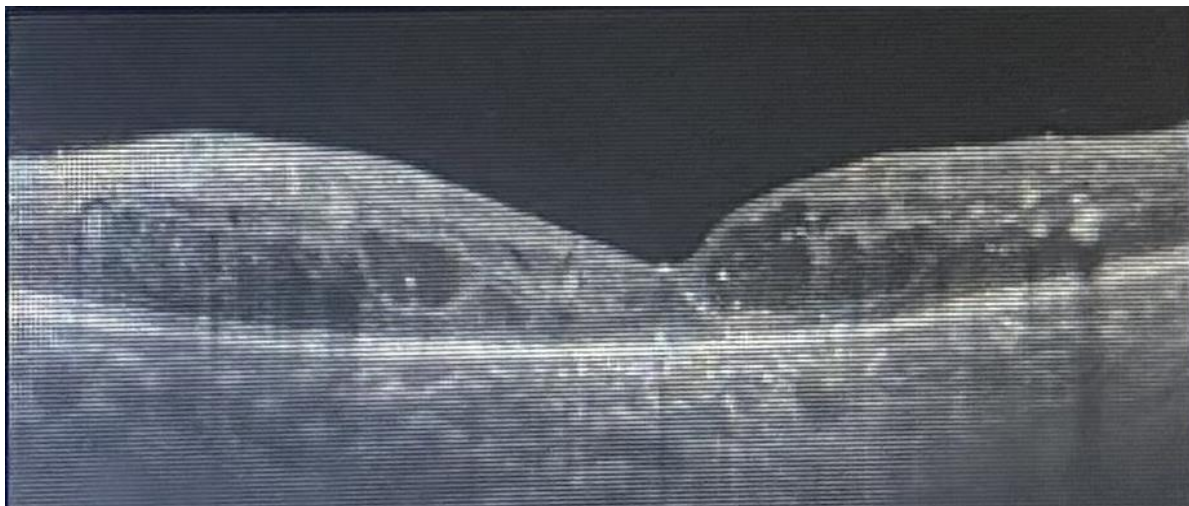


Figure 1. Identification of disorganization of retinal inner layers (DRIL) on optical coherence tomography (OCT).

Diabetic Macular Edema (DME) was found in 60 (62.5%) patients. There was a significant association between the existence of diabetic macular edema and DRIL ( $p < 0.001$ , Phi/Cramer's  $V = 0.698$ ). Likewise, there was a strong positive

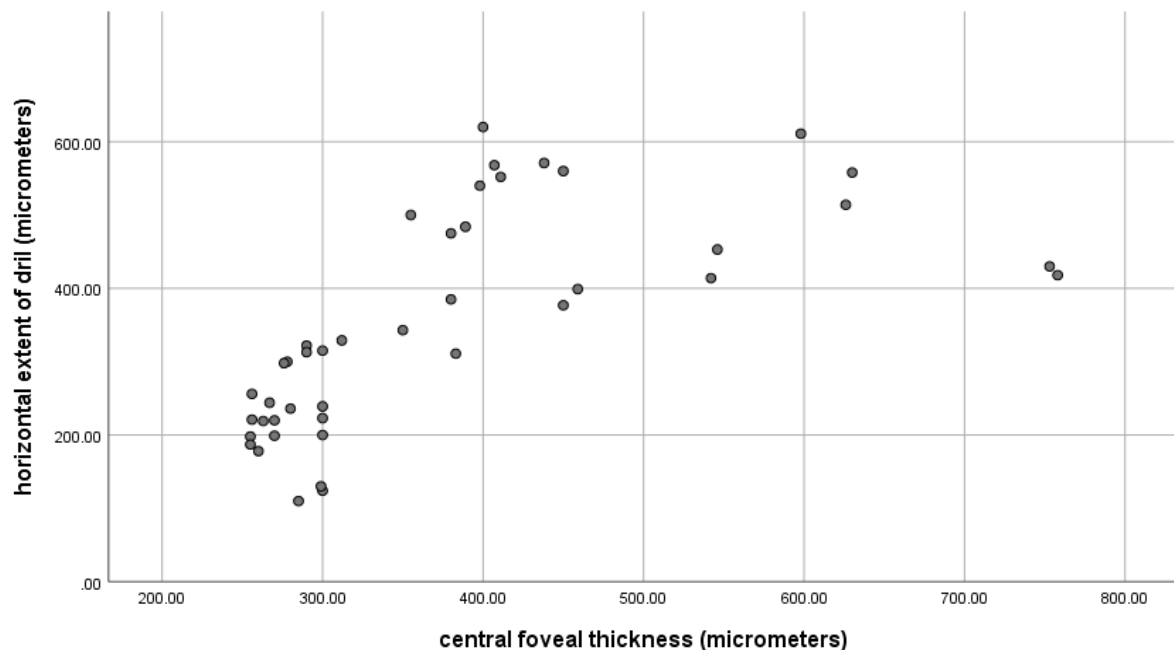
correlation (Pearson's) between central foveal thickness in micrometers and horizontal extent of DRIL in micrometers, which was statistically significant,  $r = 0.66$ ,  $n = 96$ ,  $p < 0.001$  (Figure 2). Furthermore, One-way ANOVA revealed that there were

statistically significant differences in the means of central foveal thickness (micrometers) across the different visual acuity groups,  $F(3, 92) = 87.64$ ,  $p < 0.001$ , partial eta squared = 0.741. A Tukey post hoc test revealed significant differences across all visual acuity groups (Table 1). Similarly, there was significant difference in the mean horizontal extent of DRIL (micrometers) across the different visual

acuity groups,  $F(2, 40) = 69.05$ ,  $p < 0.001$ , partial eta squared = 0.775. A Tukey post hoc test revealed significant differences across all visual acuity groups (Table 1). One way ANCOVA revealed that there was significant difference in the mean horizontal extent of DRIL across different visual acuity groups while adjusted for mean central foveal thickness,  $F(2, 39) = 29.42$ ,  $p < 0.001$ , partial eta squared = 0.601.

*Table 1. The mean values of central foveal thickness and horizontal extent of DRIL across different visual acuity groups.*

Visual acuity	Central foveal thickness (μm)			Horizontal extent of DRIL (μm)		
	No.	Mean	SD	No.	Mean	SD
6/6-6/9	43	208.88	37.33	0	-	-
6/12-6/18	27	293.18	32.07	17	210.58	57.70
6/24-6/36	14	370.35	77.11	14	374.71	88.54
6/60 or lesser	12	532.00	139.01	12	526.50	68.20
P value	$p < .001$			$p < .001$		



**Figure 2.** Scatter plot of horizontal extent of DRIL (micrometers) by central foveal thickness (micrometers)

### Discussion:

Retinal inner layers play a crucial role in transmitting visual signals through neurons, and such transmission is dependent on the integrity of individual retinal layers. DRIL, as already described, disrupts the retinal inner layers and worsens retinal function. Research suggests that DRIL is characterized by significant morphological damage to Müller cells, rather than other retinal cells like microglia or neurons. Notably, Müller cells are the first to be impacted by intracellular edema in DME. Once activated, these cells release toxic substances that trigger a cascade of events, including inflammation, blood-retinal barrier disruption, glial dysfunction, and neuronal cell death, highlighting their crucial role in the disease's progression <sup>6</sup>. DRIL has been extensively studied in a variety of retinal diseases like diabetic retinopathy, retinal vein occlusion, uveitis, and epiretinal membrane <sup>10 11</sup>. In our study, the frequency of DRIL was 44.8%. this is compatible with another study done in type 2 diabetics, where the frequency reported was 52.63% <sup>6</sup>. In another study, done in both type 1 and type 2 diabetics, DRIL was found in 48.1% of the patients <sup>12</sup>. The slight discrepancy in prevalence rates may be due to differences in population demographics, study design, sampling methods or data analysis. Similarly, another small case-control study reported the frequency of DRIL as 16% <sup>13</sup>. Our study also revealed that type 2 diabetics had more extensive DRIL than type 1 diabetics, but this finding was not observed in other studies. The plausible explanation for this could be that the propensity of type 2 diabetes to be diagnosed later in life, coupled with potential prolonged periods of inadequate glycemic control, is often cited as a contributing factor to the accelerated progression of retinal damage and further, because diabetic macular edema is more common in type 2 diabetes <sup>14</sup>.

Chronicity plays a crucial role in the development of DRIL. Research reveals that patients with a longer disease duration

have a significantly higher incidence of DRIL. Our study also advocated this finding, as patients who developed DRIL had a longer duration of diabetes <sup>1</sup>. Although Disorganization of the Retinal Inner Layers (DRIL) has been extensively investigated as a surrogate biomarker for visual acuity in diabetic macular edema, our study yields a novel finding: a significant association between central foveal thickness (central subfield thickness) and the extent of DRIL in SD-OCT scans. This correlation is intriguing, as previous research suggested that sub retinal fluid and DRIL do not coexist due to DRIL's role as a marker of chronic diabetic macular edema. However, other studies have reported that persistent intraretinal cysts predict the development of DRIL. Given that increased central foveal thickness can result from sub retinal fluid, intraretinal cysts, or both, our findings imply that elevated central foveal thickness is linked to the development of DRIL <sup>7</sup>.

Our study revealed that patients with extensive DRIL had poorer baseline visual acuity which is consistent with previous researches which have shown that the presence and extent of DRIL on OCT scans are strongly correlated with visual acuity outcomes in patients with DME. Patients with more extensive DRIL are less likely to achieve significant visual gains with treatment. The extent of Disorganization of the Retinal Inner Layers (DRIL) within the central 1mm of the fovea exhibits a robust correlation with visual acuity, even when adjustments are made for retinal thickness. Notably, early alterations in foveal DRIL extent have been found to be predictive of long-term visual outcomes. This association remains significant, irrespective of whether eyes exhibit reduced vision subsequent to edema resolution or maintain good vision despite the presence of concurrent edema. This suggests that DRIL extent is a critical determinant of visual acuity, independent of edema status <sup>1 9</sup>.

Anti-VEGF therapy has been shown to effectively reduce macular thickness and improve visual acuity in patients with diabetic macular edema (DME). However, response to treatment varies, with some patients experiencing significant improvement, while others show moderate or minimal response. Studies have found that patients with more extensive retinal layer disruption (DRIL) tend to have poorer treatment outcomes. Furthermore, some patients may not experience visual recovery despite successful DME treatment. The relationship between anti-VEGF therapy and DRIL is complex, with conflicting evidence on its impact. One study reported no significant change in DRIL even after multiple injections of anti-VEGF<sup>15</sup>. Recent research suggests that treatment with a DEX implant may improve DRIL, potentially by promoting Müller cell recovery<sup>7</sup>. This reveals that Müller cells are more resilient than neurons, and their morphological recovery can be detected as a restoration of DRIL. These findings support the notion that DRIL initially originates from Müller cell disruption, before involving bipolar cells, and highlight the potential for recovery. However, neuronal function and integrity may also be compromised later in the disease process, with limited potential for restoration. Thus, understanding the baseline characteristics that predict treatment response is essential, particularly in identifying patients at risk of poor outcomes.

Although this study provides valuable insights, its cross-sectional design constitutes a limitation. To elucidate the dynamic relationship between visual acuity and DRIL, as well as the responsiveness of DRIL to conventional macular edema treatments, longitudinal studies are warranted. These future investigations will enable the prediction of trends in visual acuity in relation to changes in DRIL, ultimately informing the development of more effective treatment strategies.

## Conclusion:

This study validates the utility of DRIL as a potential biomarker. The extent of DRIL is correlated with severity of DME, making it a useful marker for disease progression. DRIL can be used to monitor treatment response in patients with DME allowing clinicians to adjust treatment strategies accordingly. Emerging evidence suggests that early intervention can potentially reverse DRIL, underscoring the importance of incorporating DRIL assessment into routine clinical practice to optimize patient outcomes.

## References:

1. Sun JK, Lin MM, Lammer J, et al. Disorganization of the retinal inner layers as a predictor of visual acuity in eyes with center-involved diabetic macular edema. *JAMA Ophthalmol.* November 2014;132(11):1309-16.
2. Ishibashi T, Sakimoto S, Shiraki N, Nishida K, Sakaguchi H, Nishida K. Association between disorganization of retinal inner layers and visual acuity after proliferative diabetic retinopathy surgery. *Sci Rep.* Aug 2019;22(9).
3. Alasil T, Keane P, Updike J, et al. Relationship between optical coherence tomography retinal parameters and visual acuity in diabetic macular edema. *Ophthalmology.* December 2010;117(12):2379-86.
4. Saxena S, Srivastav K, Cheung C, Ng J, Lai T. Photoreceptor inner segment ellipsoid band integrity on spectral domain optical coherence tomography. *Clin Ophthalmol.* Dec 2014;9(8):2507-22.
5. Das R, Spence G, Hogg RE, Stevenson M, Chakravarthy U. Disorganization of Inner Retina and Outer Retinal Morphology in Diabetic Macular Edema. *JAMA Ophthalmol.* Feb. 2018;136(2):202-208.
6. Midena E, Torresin T, Schiavon S, et al. The Disorganization of Retinal Inner Layers Is Correlated to Müller Cells Impairment in Diabetic Macular

- Edema: An Imaging and Omics Study. *Int J Mol Sci.* June 2023;1(24):9607.
7. Zur D, Iglicki M, Sala-Puigdollers A, et al. Disorganization of retinal inner layers as a biomarker in patients with diabetic macular oedema treated with dexamethasone implant. *Acta Ophthalmol.* March 2020;98(2):217-223.
  8. Santos A, Costa M, Schwartz C, et al. Optical coherence tomography baseline predictors for initial best-corrected visual acuity response to intravitreal anti-vascular endothelial growth factor treatment in eyes with diabetic macular edema. *Retina.* June 2018;38(6):1110–1119.
  9. Radwan SH, Soliman AZ, Tokarev J, Zhang L, van Kuijk F, Koozekanani DD. Association of Disorganization of Retinal Inner Layers With Vision After Resolution of Center-Involved Diabetic Macular Edema. *JAMA Ophthalmol.* July 2015;133(7):820-5.
  10. Babiuch AS, Han M, Conti FF, Wai K, Silva FQ, Singh RP. Association of Disorganization of Retinal Inner Layers With Visual Acuity Response to Anti-Vascular Endothelial Growth Factor Therapy for Macular Edema Secondary to Retinal Vein Occlusion. *JAMA Ophthalmol.* January 2019;137(1):34-86.
  11. Huanhuan L, Conghui Z, Hui L, Shuai Y, Yao L, Fang W. Effects of disorganization of retinal inner layers for Idiopathic epiretinal membrane surgery: the surgical status and prognosis. *BMC Ophthalmol.* March 2023;28:108.
  12. Katharina W, Lilith PA, Leon AvdE, Marlene S, Frank GH, Thomas A. Characterizing the disorganization of the retinal inner layers in diabetic retinopathy: using a new high-resolution optical coherence tomography device. *Invest. Ophthalmol. Vis. Sci.* June 2024;65(7):3199.
  13. Katherine AJ, Christopher AS, Vinícius MdC, et al. Disorganization of Retinal Inner Layers (DRIL) and Neuroretinal Dysfunction in Early Diabetic Retinopathy. *Invest. Ophthalmol. Vis. Sci.* November 2018;59(13):5481-5486.
  14. Nentwich MM, Ulbig MW. Diabetic retinopathy - ocular complications of diabetes mellitus. *World J Diabetes.* April 2015;6(3):489-99.
  15. Wirth MA, Wons J, Freiberg FJ, Becker MD, Michels S. IMPACT OF LONG-TERM INTRAVITREAL ANTI-VASCULAR ENDOTHELIAL GROWTH FACTOR ON PREEXISTING MICROSTRUCTURAL ALTERATIONS IN DIABETIC MACULAR EDEMA. *Retina.* September 2018;38(9):1824-1829.

#### **Authors Contribution**

Concept and design: Mazhar Ul Hassan  
 Data collection/assembly: Muhammad SharjeeNimra Akram  
 Drafting: Nimra Akram  
 Statistical Expertise: Mazhar Ul Hassan  
 Critical revision: Nimra Akram