



ASJO

ISSN 3006-2543 (Online)

ISSN 1990-3863 (Print)

AL-SHIFA JOURNAL OF OPHTHALMOLOGY

An Open Access, Peer Reviewed, Quarterly Journal of
AL-SHIFA TRUST EYE HOSPITAL

Vol. 20, No. 3, July – September 2024

Indexed in

WHO Index Medicus (IMEMR)

Asian Digital Library (ADL)

Pak Medinet

Pakistan Medical and Dental Council IP/033

ISSN 3006-2543 (Online)
ISSN 1990-3863 (Print)

**A
S
J
O**

Al-Shifa Journal of Ophthalmology

Vol. 20, No. 3, July – September 2024

QUARTERLY PUBLISHED

- **Editorial: Ethical Consideration in Research and Practice**
- **Biometry Formulas in High Myopes**
- **Anterior Lamellar Recession vs. Blepharoplasty**
- **Risks for Multiple Sessions of Retinal Photocoagulation**
- **Refractive Error in Healthy Infants of Nepal**
- **Central Corneal Thickness: Ultrasound vs. Optical Pachymetry**
- **Ocular Manifestations of Noonan Syndrome**

Abstracts available at <https://www.asjoalshifaeye.org> and <http://www.pakmedinet.com/ASJO>
Manuscript submission through online platform ejmanager.com

Indexed in Index Medicus -EMR

Recognized by Pakistan Medical & Dental Council – IP/033

Al-Shifa Journal of Ophthalmology

Editorial inquiries should be addressed to Prof. Dr. Tayyab Afghani, Department of Orbit and Oculoplastics, Al-Shifa Trust Eye Hospital, Jhelum Road Rawalpindi, Pakistan.
Tel: 0092 51 5487821-25, Fax: 0092 51 5487827; Email: aqrcpio@yahoo.com ;
Website: www.asjoalshifaeye.org

Editorial: Ethical Considerations in Ophthalmic Research and Practice Mahmood Ali	86
Mean Errors From The Target Refraction at 1 Month After Phacoemulsification Surgery in High Myopes: A Comparison Of SRK/T, Haigis And Holladay 1 Shafaq Najmi, Badaruddin Athar Naem, Tehmina Nazir, Fariha Taimur, Zawar Ali Rathore	88
Comparison of Anterior Lamellar Recession With and Without Blepharoplasty For Upper Eyelid Cicatricial Entropion Asima Rafique, Muhammad Shaheer	93
Obesity, Physical Inactivity, and Duration of Diabetes Mellitus as Risk Factors For Multiple Sessions of Retinal Photocoagulation Muhammad Kamran Khalid, Muhammad Marwat, Muhammad Sharjeel Mansoori, Muhammad Usman Awan, Uroosa Kanwal	101
Refractive Error Among Healthy Infants in Tertiary Eye Care Centre of Nepal Dr Govind Gurung, Krishna Kant Gupta, Harikant Sah	106
Comparison of Central Corneal Thickness Using Ultrasound and Optical Pachymetry Nashmia Jalil Malik, Muhammad Azam Khan, Irfan Aslam Khattak, Ayisha Shakeel, Huma Zainab, Maria Saleem	111
Ocular Features of A Rare Case of Noonan Syndrome in A Pakistani Population Murtaza Sameen Junejo	119

Comparison of Anterior Lamellar Recession With and Without Blepharoplasty For Upper Eyelid Cicatricial Entropion

Asima Rafique¹, Muhammad Shaheer²

Abstract:

Objectives: To compare the success rate and cosmetic outcomes of anterior lamellar recession versus anterior lamellar recession plus blepharoplasty for treatment of cicatricial entropion of the upper eyelid.

Methods: This Quasi-Experimental study, after approval of the ethics committee of the institute, was carried out between 1st February 2022 to 30th June 2023 at the Institute of Ophthalmology, Mayo Hospital, Lahore. Eighteen patients presenting to the Institute of Ophthalmology and diagnosed with cicatricial entropion were selected for surgery. The subjects were divided into two groups 1 and 2. Group 1 patients underwent anterior lamellar recession alone while group 2 had anterior lamellar recession combined with blepharoplasty. Patients diagnosed with any coexisting senile entropion or ectropion were excluded from the study.

Results: Group 2, which underwent anterior lamellar recession with blepharoplasty, exhibited higher rates of complete success (77.8%) compared to Group 1 (44.4%), ($p=0.43$). Aesthetic outcomes favored Group 2, with 66.7% of patients in this group rated as having a good aesthetic outcome, compared to only 22.2% in Group 1. When evaluating post-operative success by grade, in Group 1, those with Grade 1 entropion exhibited a success rate of 60%, however, in Group 2, all Grade 1 cases achieved complete success.

Conclusion:

There is no significant difference between anterior lamellar recession with blepharoplasty and without blepharoplasty for upper eyelid cicatricial entropion. *Al-Shifa Journal of Ophthalmology 2024; 20(3): 93-100. © Al-Shifa Trust Eye Hospital, Rawalpindi, Pakistan.*

-
1. Sir Gangaram Hospital, Lahore.
 2. College of Ophthalmology & Allied Vision Sciences, Lahore.
-

Originally Received: 05 June 2024

Revised: 27 June 2024

Accepted: 31 June 2024

Correspondence to:

Muhammad Shaheer

College of Ophthalmology & Allied Vision Sciences, Lahore.

Introduction:

Entropion is a pathology of eyelids in which the lids are turned inwards so that the pilosebaceous unit is touching the globe (cornea).¹ It can involve upper and lower eyelids separately or both eyelids simultaneously. Various variants of entropion have been described in literature with each having its distinct pathophysiology and incidence as high as 2% in some communities. Some common types include involitional or senile, congenital, spastic or cicatricial entropion.² Common pathologic mechanisms include laxity of horizontal and vertical lids, weakening of lid retractors, and overriding of parts of orbicularis oculi muscle.³ Cicatricial entropion results from scarring and fibrosis of posterior lamella secondary

to a localized or systemic inflammatory condition.⁴

Treatment of cicatricial entropion depends upon the degree of involvement, grade of severity (mild-minimal lid laxity, moderate-scleral show, marked-punctal eversion, and extreme-with scarring), and symptoms of patients affecting one's daily life.⁵ A variety of surgical treatment options are in practice worldwide ranging from lash follicle excision⁶ for segmental involvement to tarsal fracture & rotation, anterior lamellar recession & blepharoplasty for severe cases.⁷

For very severe disease, posterior lamella needs to be enlarged by release of scar tissue with or without of grafting of a membrane. As with any surgery, cicatricial entropion surgery also has its side effects, one of which is recurrence and over or under-correction thereby affecting the daily life of patients.⁸

The anterior lamellar recession has a good success rate in the treatment of mild to moderate cicatricial entropion. During this procedure, the lid is split by separating skin and orbicularis muscle from the tarsal plate followed by the recession of the anterior lamella. If there is excess skin overhanging the lids margin, it may compromise the surgical success rate so additional blepharoplasty may be done for such cases.⁹

Aghai et al¹⁰ in their prospective interventional case series documented 75% success rate of anterior lamellar recession & blepharoplasty for cicatricial entropion. However, no local study on this topic was found which prompted the authors to carry out this research.

Materials and Methods:

This quasi-experimental study was conducted from 1st February 2022 to 30th June 2023 at the Institute of Ophthalmology, Mayo hospital, Lahore after obtaining ethical approval vide no 2165/2022. A sample size of 18 was calculated by using a 5% level of significance and 80% power of the study by

considering aesthetic outcome as 0.318 and 0.773 in both groups.¹¹

Eighteen subjects above 40 years of age, presenting to the Institute of Ophthalmology and diagnosed with cicatricial entropion were selected for surgery. Subjects who did not give consent and those who had ectropion and entropion other than cicatricial variant were excluded. The subjects were divided into two groups namely 1 and 2. Group 1 patients underwent anterior lamellar recession alone while group 2 had anterior lamellar recession combined with blepharoplasty. Patients diagnosed with any coexisting senile entropion, or ectropion were excluded from the study.

All patients underwent surgery under local anesthesia. After aseptic measures, an incision was made with the help of a blade and scalpel at the grey line extending from the punctum towards the lateral canthus. The second incision was made at the skin crease followed by blunt dissection till the tarsal plate communicated with the grey line incision. The recession of the anterior lamella was done 4 mm and was subsequently sutured to the tarsal plate. Later, the skin crease incision was closed. In group 2, additional markings for blepharoplasty were made and skin plus orbicularis from that area were excised. Patients were advised to use antibiotic eye drops, lubricant eye drops and antibiotic/steroid combination skin ointment for incision for two weeks. Patient Satisfaction was assessed in terms of relieving of patient's symptoms on history. Data were entered and analyzed in SPSS version 25. Descriptive statistics were presented as frequency and percentages. A p-value of less than 0.05 was considered significant and was checked by applying Fischer's exact test.

Results:

Demographic characteristics revealed comparable mean ages between the groups, with Group 1 averaging 55.2 ± 5.26 years and Group 2 averaging 56.7 ± 4.35 years. In

terms of gender distribution, both groups exhibited a slight male predominance, with 55.6% males and 44.4% females in Group 1 and 44.4% males and 55.6% females in Group 2 (Table 1).

Post-operative success rates demonstrated notable differences between the two groups. Group 2, which underwent anterior lamellar recession with blepharoplasty, exhibited higher rates of complete success (77.8%) compared to Group 1 (44.4%). However, Statistical analysis indicated a p-value of 0.43, suggesting no significant difference between the groups in terms of post-operative success, as shown in Table 2. Regarding patient satisfaction, Group 2 also showed higher levels of satisfaction, with 77.8% of patients reporting satisfaction compared to 44.4% in Group 1. Statistical analysis yielded a p-value of 0.43, indicating no significant difference in patient satisfaction between the groups (Table 2).

Aesthetic outcomes favored Group 2, with 66.7% of patients in this group rated as having a good aesthetic outcome, compared to only 22.2% in Group 1. Conversely, 66.7% of patients in Group 1 had fair

aesthetic outcomes, while only 33.3% fell into this category in Group 2. Statistical analysis revealed a p-value of 0.153, indicating a trend towards better aesthetic outcomes in Group 2, although not statistically significant (Table 2). When evaluating post-operative success by grade, in Group 1, those with Grade 1 entropion exhibited a success rate of 60%, however, in Group 2, all Grade 1 cases achieved complete success. In Grade 2 cases, both groups had comparable success rates. Regarding age, participants aged 45-55 years in both groups demonstrated similar post-operative success rates, while those above 55 years showed higher success rates in Group 2, although not statistically significant.

In summary, while there were some trends favoring anterior lamellar recession with blepharoplasty, particularly in Grade 1 cases and in certain demographic groups, the differences were not statistically significant. Further research with larger sample sizes may provide additional insights into the effectiveness of these surgical techniques.

Table 1- Demographic characteristics of the study participants

Group	Age in years (Mean ± SD)	Gender n (%)	
		Male	Female
1(without)	55.2 ± 5.26	5 (55.6%)	4 (44.4%)
2 (with)	56.7 ± 4.35	4 (44.4%)	5 (55.6%)

Table 2- Post-Operative Success, Patient Satisfaction, Aesthetic Outcome

	Group 1 (without) n = 9	Group 2 (with) n = 9	P- value
Post-Operative success			
Complete	4 (44.4%)	7 (77.8%)	0.43
Partial	3 (33.3%)	2 (22.2%)	
Failure	2 (22.2%)	0 (0.0%)	
Patient Satisfaction			
Satisfied	4 (44.4%)	7 (77.8%)	0.43
Partially Satisfied	3 (33.3%)	2 (22.2%)	
Not Satisfied	2 (22.2%)	0 (0.0%)	
Aesthetic Outcome			
Good	2 (22.2%)	6 (66.7%)	0.153
Fair	6 (66.7%)	3 (33.3%)	
Poor	1 (11.1%)	0 (0.0%)	

Fisher's exact test was applied to check for statistical significance. P values of less than 0.05 were considered significant.

Table 3- Comparison of post-operative success stratified over age, gender and grade

	Group 1 (without) n = 9			Group 2 (with) n = 9			P-value
	Post-Operative success			Post-Operative success			
	Complete	Partial	Failure	Complete	Partial	Failure	
Grade							
Grade 1	3 (60%)	1 (20%)	1 (20%)	5 (100%)	0 (0%)	0 (0%)	0.44
Grade 2	1 (25.0%)	2 (50.0%)	1 (25.0%)	2 (50.0%)	2 (50.0%)	0 (0%)	1.00
Age							
45-55 Years	3 (60%)	2 (40.0%)	0 (0.0%)	2 (66.7%)	1 (33.3%)	0 (0.0%)	1.00
>55 years	1 (25.0%)	1 (25.0%)	2 (50%)	5 (83.3%)	1 (16.7%)	0 (0.0%)	0.11
Gender							
Male	1 (20%)	3 (60%)	1 (20%)	4 (100%)	0 (0.0%)	0 (0.0%)	0.08
Female	3 (75%)	0 (0.0%)	1 (25%)	3 (60%)	2 (40%)	0 (0.0%)	0.44

P values were calculated using Fisher's exact test

Table 4- Comparison of Patient satisfaction stratified over age, gender and grade.

	Group 1 (without) n = 9			Group 2 (with) n = 9			P-value
	Patient satisfaction			Patient satisfaction			
	Satisfied	Partially satisfied	Not satisfied	Satisfied	Partially satisfied	Not satisfied	
Grade							
Grade 1	4 (80%)	0 (0.0%)	1 (20%)	5 (100%)	0 (0.0%)	0 (0.0%)	1.00
Grade 2	0 (0.0%)	3 (75%)	1 (25%)	2 (50%)	2 (50%)	0 (0.0%)	0.42
Age							
45-55 Years	3 (60%)	2 (40%)	0 (0.0%)	2 (66.7%)	1 (33.3%)	0 (0.0%)	1.00
>55 years	1 (25%)	1 (25%)	2 (50%)	5 (83.3%)	1 (16.7%)	0 (0.0%)	0.11
Gender							
Male	2 (40%)	2 (40%)	1 (20%)	4 (100%)	0 (0.0%)	0 (0.0%)	0.28
Female	2 (50%)	1 (25%)	1 (25%)	3 (60%)	2 (40%)	0 (0.0%)	1.00

P values were calculated using Fisher's exact test

Table 5- Comparison of Aesthetic Outcome stratified over age, gender and grade.

	Group 1 (without) n = 9			Group 2 (with) n = 9			P- value
	Aesthetic Outcome			Aesthetic Outcome			
	Good	Fair	Poor	Good	Fair	Poor	
Grade							
Grade 1	2 (40%)	3 (60%)	0 (0.0%)	4 (80%)	1 (20%)	0 (0.0%)	0.52
Grade 2	0 (0.0%)	3 (75%)	1 (25%)	2 (50%)	2 (50%)	0 (0.0%)	0.42
Age							
45-55 Years	1 (20%)	4 (80%)	0 (0.0%)	2 (66.7%)	1 (33.3%)	0 (0.0%)	0.46
>55 years	1 (25%)	2 (50%)	1 (25%)	4 (66.7%)	2 (33.3%)	0 (0.0%)	0.33
Gender							
Male	1 (20%)	4 (80%)	0 (0.0%)	2 (50%)	2 (50%)	0 (0.0%)	0.52
Female	1 (25%)	2 (50%)	1 (25%)	4 (80%)	1 (20%)	0 (0.0%)	0.28

P values were calculated using fisher’s exact test

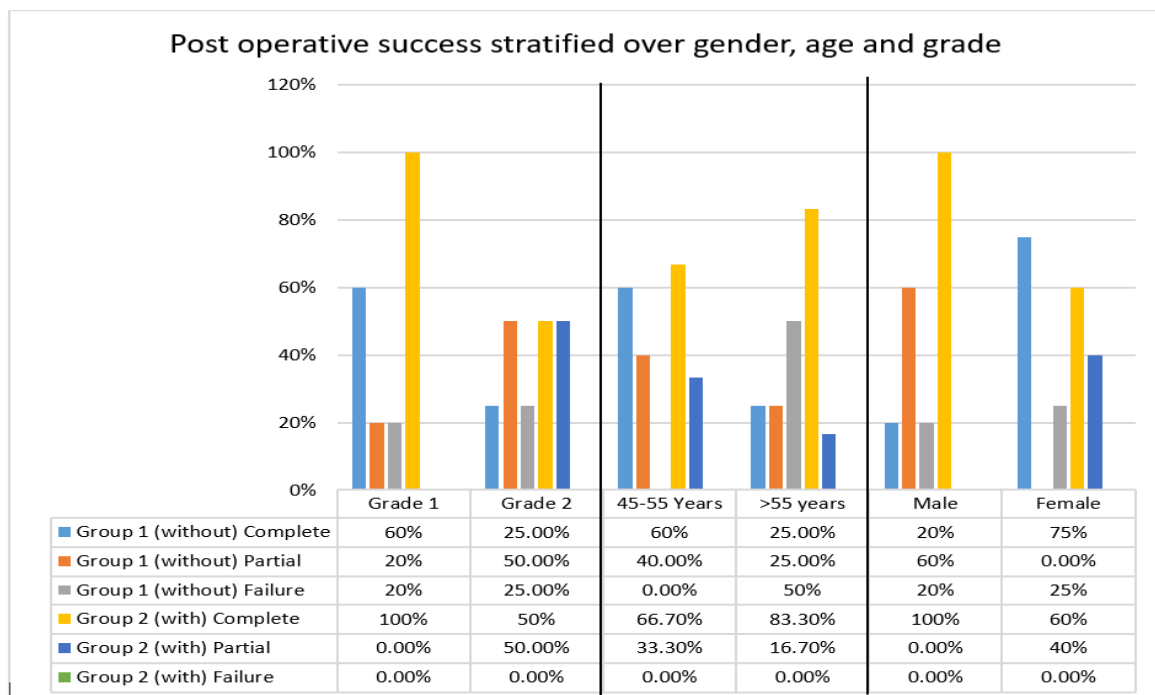


Figure 1. Post operative success of both groups stratified over gender, age and entropion grade.

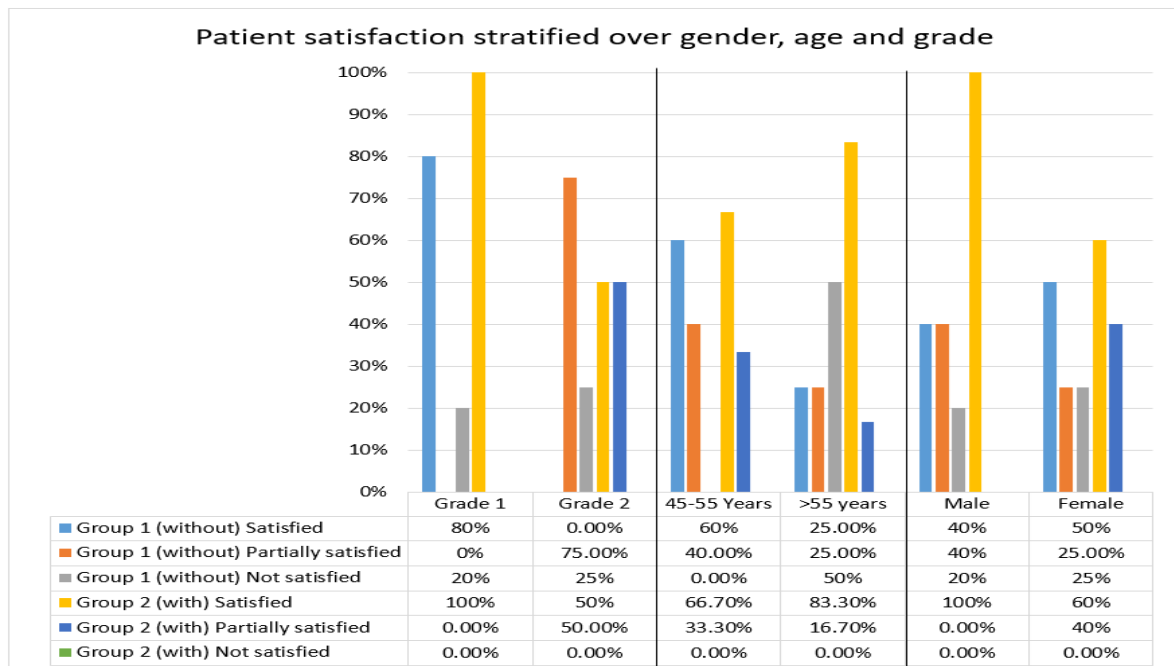


Figure 2. Patient satisfaction in both groups stratified over gender, age and entropion grade.

Discussion:

Gawdat T and colleagues¹² carried out a retrospective analysis of patients who underwent anterior lamellar recession for treatment of cicatricial entropion and evaluated surgical success and aesthetic outcomes in terms of patient satisfaction. They reported 96.8% patient satisfaction rate in terms of cosmetic outcomes. None of the cases was diagnosed postoperatively by entropion or lagophthalmos. However, 5.2% of cases had flap necrosis.

Awny I¹³ in a prospective randomized study compared the success rate of two surgical techniques for correction of upper eyelid cicatricial entropion. The techniques were anterior lamellar recession versus tarsal fracture and rotation. A 70% percent success rate was reported in patients who underwent anterior lamellar recession as no skin was touching the globe. In contrast, tarsal fracture technique yielded a 50% success rate. In another prospective interventional research, El Samkary MA¹⁴ compared success and aesthetic outcomes after anterior lamellar recession with and without blepharoplasty. It was reported that anterior lamellar recession reported 100% success and aesthetic outcomes when done with blepharoplasty. Anterior lamellar

recession alone gave 70% success rate and 60% patient satisfaction in their study.

Chan KK and associates¹⁵ studied the long-term success rate and safety of combined surgery for cicatricial entropion and blepharochalasis. The procedure performed was anterior lamellar recession, tarsal rotation and posterior lamellar advancement. Over a follow up period of four years, no eye developed recurrence of disease. However, lagophthalmos, suture granuloma, trichiasis was noted in 1 patient respectively which was treated subsequently. It was concluded that combined surgery for treatment of cicatricial entropion and blepharochalasis was safe and effective. In another research, Mohammad Farid Abulnaga A et al¹⁶ compared anterior lamellar recession with and without blepharoplasty for treatment of cicatricial entropion. The results showed 10% recurrence rate over a follow up period of 3 months in patients who underwent anterior lamellar recession alone as compared to no recurrence when the surgery was done with blepharoplasty.

Singh S and colleagues¹⁷ studied a modified technique for repair of cicatricial entropion. In their study, patients underwent anterior lamellar recession and reconstruction by labial mucosal grafting for spacing the

ciliary margin. Post operatively only one patient was noted having focal trichiasis of eye lashes which was accordingly treated. In a randomized controlled trial, Abdelaziz FM et al¹⁸ compared anterior lamellar recession with posterior lamellar tarsal rotation for treatment of cicatricial entropion. Post-operative trichiasis was higher in those who underwent posterior tarsal rotation (14.3% vs 0%; p= 0.048, 25% vs 0%; p= 0.004, 35.7% vs 10%; p= 0.019, respectively). In a similar study, Ezzeldin ER and associates¹⁹ anterior lamellar recession with bilamellar tarsal plate rotation for upper eyelid trichiasis. In the immediate postoperative period and on subsequent follow-ups, the anatomical correction rate was better in the anterior lamellar recession group while the tarsal rotation group had cases of under and over-correction. Researchers concluded that anterior lamellar recession was superior to tarsal rotation in the management of cicatricial entropion.

Sendul SY and colleagues²⁰ studied another technique in which they assessed results of anterior lamellar recession augmented with anterior tarsal rotation. The most recurring symptoms before surgery were watering, irritation in the eyes and photophobia. Ten patients had corneal opacity and erosion, and 1 patient had only epithelial erosion. Postoperatively, all patient's pre-operative symptoms had been resolved with none of them reporting eyelid contour disorders, ectropion, or recurring entropion.

In a video correspondence to a research journal, Adewara B and Singh S²¹ emphasized that anterior lamellar recession combined with mucous membrane grafting yields better results and proposed that it should be done in all cases of cicatricial entropion for good aesthetic outcome.

Conclusion:

There is no significant difference between anterior lamellar recession with blepharoplasty and without blepharoplasty for upper eyelid cicatricial entropion in the

context of aesthetic outcomes, patient satisfaction and surgical success rate.

References:

1. Yang MK, Sa HS, Kim N, Jeon HS, Hyon JY, Choung H, et al. Quantitative analysis of morphological and functional alterations of the meibomian glands in eyes with marginal entropion. *Plos one*. 2022;17(4):e0267118.
2. McKelvie J, Papchenko T, Carroll S, Ng SG. Cicatricial ectropion surgery: a prospective study of long-term symptom control, patient satisfaction and anatomical success. *Clin & Exp Ophthalmol*. 2018;46(9):1002-7.
3. Saskia TI, Iskandar E. Characteristics of Entropion Patients at Dr. Mohammad Hoesin General Hospital: A Descriptive Study. *Sriwijaya J Ophthalmol*. 2022;5(2):206-10.
4. Iyengar SS, Hamill EB, Dresner SC. Entropion. *Smith & Nesi's Ophthalmic Plast Reconst Surg*. 2021:181-187.
5. Kooistra LJ, Scott JF, Bordeaux JS. Cicatricial ectropion repair for dermatologic surgeons. *Dermatol Surg*. 2020;46(3):341-7.
6. Singh S, Basu S, Jakati S. Cicatricial Entropion in Chronic Cicatrizing Conjunctivitis: Potential Pathophysiologic Mechanisms and Long-Term Outcomes of a Modified Technique. *Ophthalmic Plast & Reconst Surg*. 2023:10-97.
7. Ibrahim EN, Tharwat E, Khalil MM, Mohammed AR, Mohammed MF, Alkady AM, et al. Modified Anterior Lamellar Recession for All Grades of Upper Eyelid Trachomatous Cicatricial Entropion. *Clin Ophthalmol*. 2023 Dec:2323-32.
8. Behera G, Sangaraju S, Meethale Thiruvoth F, Kasturi N, Babu KR. Vision and ocular surface salvage in extreme postburn cicatricial ectropion with infectious exposure keratitis. *J Burn Care & Res*. 2021;42(4):836-8.
9. Sobti M, Joshi N. Lower Eyelid Blepharoplasty: Minimizing

- Complications and Correction of Lower Eyelid Malposition. *Facial Plastic Surgery*. 2023;39(01):028-46.
10. Aghai GH, Gordiz A, Falavarjani KG, Kashkouli MB. Anterior lamellar recession, blepharoplasty, and supratarsal fixation for cicatricial upper eyelid entropion without lagophthalmos. *Eye*. 2016;30(4):627-31.
 11. Elessawy KB, Elnagar AM, Nasr HE, Abdelbaky SH. Anterior lamellar recession with and without blepharoplasty in upper eyelid cicatricial entropion. *J Egypt Ophthalmol Soc*. 2021;114(4):93-100.
 12. Gawdat TI, Kamal MA, Saif AS, Diab MM. Anterior lamellar recession for management of upper eyelid cicatricial entropion and associated eyelid abnormalities. *Int J Ophthalmol*. 2017;10(12):1830.
 13. Awny I. Anterior lamellar recession versus tarsal fracture for management of recurrent cicatricial upper lid entropion: A randomized comparative study. *Egyptian J Clin Ophthalmol*. 2020;3(2):97-101.
 14. El Samkary MA, Rashad SM, Abd Elhamid MA, El-neaey SH. A comparative study between anterior lamellar repositioning and anterior lamellar repositioning with blepharoplasty in management of upper eyelid entropion trichiasis. *Egyptian J Hosp Med*. 2018;72(4):4407-12.
 15. Chan KK, Li CL, Chan RY, Young AL, Yip WW, Chong KK. Upper eyelid blepharoplasty, tarsal margin rotation, and posterior lamellar super-advancement for correction of severe upper eyelid cicatricial entropion and dermatochalasis. *Hong Kong J Ophthalmol*. 2020;24(2):38-43.
 16. Mohammad Farid Abulnaga A, Sobhy A, Eid Abd El-Salam M. Anterior lamellar recession for treatment of cicatricial entropion with or without blepharoplasty. *Al-Azhar Med J*. 2020;49(2):759-66.
 17. Singh S, Narang P, Mittal V. Labial mucosa grafting for lid margin, anterior lamellar, and posterior lamellar correction in recurrent cicatricial entropion. *Orbit*. 2021;40(4):301-5.
 18. Abdelaziz FM, Kamal MA, Said MM, Diab MM. Anterior Lamellar Recession versus Posterior Lamellar Tarsal Rotation for Lower Lid Trachomatous Trichiasis: A Randomized Controlled Trial. *Clin Ophthalmol*. 2020:2043-50.
 19. Ezzeldin ER, Elgazzar AF, Hussein MO, Ibrahim EN, Tharwat E. Anterior lamellar recession versus bilamellar tarsal rotation in upper lid cicatricial trichiasis. *Taiwan J Ophthalmol*. 2023.
 20. Sendul SY, Dirim B, Atılgan CU, Demir M, Olgun A, Demir ST, et al. Anterior tarsal flap rotation combined with anterior lamellar reposition in the repair of cicatricial upper eyelid entropion. *Arquivos Brasileiros de Oftalmologia*. 2018;81:47-52.
 21. Adewara B, Singh S. Severe cicatricial entropion repair using mucous membrane graft in Stevens–Johnson syndrome. *Indian J Ophthalmol*. 2022;70(12):4470.

Authors Contribution

Concept and Design: Muhammad Shaheer
Data Collection / Assembly: Asima Rafique
Drafting: Muhammad Shaheer
Statistical expertise: Asima Rafique
Critical Revision: Muhammad Shaheer