



ASJO

ISSN 3006-2543 (Online)

ISSN 1990-3863 (Print)

AL-SHIFA JOURNAL OF OPHTHALMOLOGY

An Open Access, Peer Reviewed, Quarterly Journal of
AL-SHIFA TRUST EYE HOSPITAL

Vol. 20, No. 2, April – June 2024

Indexed in

WHO Index Medicus (IMEMR)

Asian Digital Library (ADL)

Pak Medinet

Pakistan Medical and Dental Council IP/033

ISSN 3006-2543 (Online)
ISSN 1990-3863 (Print)

**A
S
J
O**

Al-Shifa Journal of Ophthalmology

Vol. 20, No. 2, April – June 2024

QUARTERLY PUBLISHED

- **Editorial: Implementing Workplace-Based Assessments**
- **Nepafenac Eyedrops After Phacoemulsification**
- **Primary Open Angle Glaucoma and Vitamin D Levels**
- **Etiology and Causative Bacteria of Microbial Keratitis**
- **Lidocaine Application in Cataract Surgery**
- **Surgical Outcomes of Phacoemulsification**

Abstracts available at <https://www.asjoalshifaeye.org> and <http://www.pakmedinet.com/ASJO>
Manuscript submission through online platform ejmanager.com

Indexed in Index Medicus -EMR

Recognized by Pakistan Medical & Dental Council – IP/033

Al-Shifa Journal of Ophthalmology

Editorial inquiries should be addressed to Prof. Dr. Tayyab Afghani, Department of Orbit and Oculoplastics, Al-Shifa Trust Eye Hospital, Jhelum Road Rawalpindi, Pakistan.
Tel: 0092 51 5487821-25, Fax: 0092 51 5487827; Email: aqrcpio@yahoo.com ;
Website: www.asjoalshifaeye.org

- Editorial: Implementing Workplace-Based Assessments in Ophthalmology: CPSP's Commendable Endeavor** 46
Mahmood Ali
- Effect of 0.1% Nepafenac Eye Drops on Macular Thickness After Uneventful Phacoemulsification Assessed by Optical Coherence Tomography** 48
Anushka Shaukat, Muhammad Azam Khan, Ayisha Shakeel, Irfan Aslam Khattak, Maria Saleem, Huma Zainab
- Primary Open-Angle Glaucoma and Serum Vitamin D Levels** 56
Masooma Talib, Aqsa Malik, Saima Rasheed, Farah Naz Tahir, Yasir Iqbal Malik, Atteaya Zaman, Anoosh Qayyum, Tehmina Qamar
- Etiology and Causative Bacteria of Microbial Keratitis in Mirpur Azad Kashmir** 61
Muhammad Asif, Sara Najeeb, Nazish Babar, Muhammad Usman Sadiq, Muhammad Irfan Sadiq, Maliha Ansari
- Effectiveness in Achieving Retrobulbar Infiltrative Anesthesia With and Without Prior Dermal application of Lidocaine on Lids in Cataract Surgery** 68
Attiqa Riaz, Muhammad Ali, Afifa Ramzan, Saira Shahzadi, Muhammad Hannan Jamil, Memoona Arshad
- Surgical Outcomes of Phacoemulsification at A Tertiary Care Eye Hospital** 75
Rebecca Murtaz, Sabihuddin Ahmad, Sana Naveed, Inam Ul Haq

Etiology and Causative Bacteria of Microbial Keratitis in Mirpur Azad Kashmir

Muhammad Asif¹, Sara Najeeb², Nazish Babar³, Muhammad Usman Sadiq², Muhammad Irfan Sadiq⁴, Maliha Ansari⁵

Abstract:

Objectives: To determine the common etiology and causative bacteria in cases of microbial keratitis in Mirpur Azad Kashmir.

Methodology: This study is a retrospective analysis of the microbiological reports of all patients at Divisional Headquarters Mirpur Azad Kashmir who were diagnosed with bacterial keratitis between January 1, 2021, and December 31, 2022. The study included demographic information, past eye trauma history, ocular surface disease, usage of contact lenses and topical steroids, recent ocular surgeries, and diabetes mellitus.

Results: In a study involving 68 patients with eye infections, the average age was 39.93 years with a higher representation of males (47) than females (21). Most cases were due to trauma (62%), followed by ocular surface disease (19%), contact lens use (9%), topical steroid use (7%), and other causes like surgery or diabetes. *Staphylococcus epidermidis* was the most common causative bacteria (47%), followed by *Streptococcus pneumoniae* (16%), *Staphylococcus aureus* (13%), *Pseudomonas aeruginosa* (10%), *Staphylococcus hominis* (9%), and *Moraxella* species (4%).

Conclusion: This study highlights the predominance of trauma as the leading cause of eye infections, with *Staphylococcus epidermidis* being the most common causative bacteria. *Al-Shifa Journal of Ophthalmology* 2024; 20(2): 61-67. © Al-Shifa Trust Eye Hospital, Rawalpindi, Pakistan.

1. Divisional Headquarters Teaching Hospital, Mirpur AJK.
2. Mohi-ud-Din Islamic Medical College, Mirpur AJK.
3. Gajju Khan Medical College, Swabi.
4. Mohtarma Benazir Bhutto Shaheed Medical College, Mirpur AJK.
5. Akhtar Saeed Medical College, Rawalpindi.

Originally Received: 22 April 2024

Revised: 21 May 2024

Accepted: 28 May 2024

Correspondence to:

Muhammad Usman Sadiq
Mohi-ud-Din Islamic Medical College,
Mirpur AJK.
Email: u_sadiq@hotmail.com

Introduction:

A dangerous eye ailment termed bacterial keratitis is defined by corneal inflammation brought on by a bacterial infection¹. It is one of the main causes of visual impairment and, if left untreated, can have serious consequences. Eye pain, redness, excessive tears, blurred vision, light sensitivity, and the feeling of something alien in the eye are common symptoms of the illness².

Wearing contact lenses, corneal damage (such as scratches or cuts), ocular surface conditions (such dry eye syndrome), and weakened immune systems are the most frequent risk factors for bacterial keratitis³. Furthermore, wearing contact lenses while swimming or sleeping increases the risk of bacterial keratitis due to incorrect use or hygiene⁴.

Although the gram-positive bacteria that cause the problem can vary, common culprits include *Staphylococcus epidermidis*, *Staphylococcus aureus*, and *Streptococcus pneumoniae*.

Severe bacterial keratitis instances have also been linked to gram-negative bacteria like *Pseudomonas aeruginosa*⁵.

A thorough eye examination is usually required for the diagnosis, which also includes corneal cultures and slit-lamp biomicroscopy to determine the precise bacteria at play^{6, 7}. Treatment entails starting broad-spectrum antibiotic eye ointments or drops right away; in severe cases, these are frequently given hourly⁸. In certain situations, steroid eye drops may be used to relieve inflammation; however, cautious monitoring is necessary to avoid the infection from getting worse⁹.

Untreated or inadequately managed bacterial keratitis can result in permanent damage necessitating corneal transplantation¹⁰, as well as complications such as corneal scarring, vision loss, and corneal perforation. Therefore, the management of bacterial keratitis and preservation of vision depends on early diagnosis, adequate treatment, and vigilant follow-up care¹¹.

Understanding the specific patterns of microbial keratitis in different regions is crucial for effective management and prevention strategies¹². This research focuses on investigating the etiology and causative bacteria of microbial keratitis in Mirpur, Azad Kashmir, an area with unique environmental and demographic characteristics.

Materials and Methods:

The research was conducted as a retrospective study at Divisional Headquarters Hospital, Mirpur Azad Kashmir after taking ethical approval, spanning from 1st January 2021 to 31st December 2022. The study included all cases of bacterial keratitis with positive

cultures. The study eliminated patients having multiple isolate cultures as well as those that were not bacterial. The study involved 68 patients in all. Age, gender, demographic data, history of previous eye injuries, ocular surface disease, use of contact lenses and topical steroids, recent ocular surgeries, and diabetes mellitus were all gathered from the patient's medical records. Information about the corneal cultures was gathered, including the organism's identity and the reason behind the microbial keratitis. Data was collected on a pre-designed proforma.

Data were analysed using SPSS version 21.0. Numerical variables like age were expressed as mean and standard deviation. Descriptive variables like gender, eye involved, etiology & causative bacteria were expressed as frequencies and percentages.

Results:

A total of 68 patients were included in this study. The mean age of patients included in this study was 39.93 ± 11.422 years (Table I). There were 47 males (30.88%) and 21 females (60.12%) in this study. The number of right eyes was 36, & 32 were left eyes (Figure 1).

Regarding Etiology, 42 (62%) were caused by Trauma, 13 (19%) by Ocular Surface Disease, 6 (9%) by Contact Lens, 5 (7%) had a history of use of Topical Steroids, 1 (1%) had a history of ocular surgery (Iatrogenic) and 1 (1%) patient had a history of uncontrolled Diabetes Mellitus (Figure 2).

Regarding Causative Bacteria, 32 (47%) were *Staphylococcus epidermidis*, 11 (16%) were *Streptococcus pneumoniae*, 9 (13%) were *Staphylococcus aureus*, 7 (10%) were *Pseudomonas aeruginosa*, 6 (9%) were *Staphylococcus hominis* and 3 (4%) were *Moraxella* Species. Table 2 shows the relationship between the etiology & causative bacteria of microbial keratitis.

Table 1: Mean age in the study (n=68)

Mean Age in the Study (Years)			
Mean	Std. Deviation	Maximum	Minimum
39.93	11.422	57	23

Table 2: Relationship between Etiology & Causative Bacteria of Microbial Keratitis

Etiology	Causative Bacteria						Total
	Staph. epidermidis	Strep. pneumoniae	Staph. aureus	P aeruginosa	Staph. hominis	Morexella Species	
Trauma	20	7	6	5	2	2	42
Ocular Surface Disease	7	4	0	0	1	0	12
Contact Lens	2	0	3	1	0	0	6
Topical Steroids	1	0	1	0	3	0	5
Iatrogenic	1	0	0	0	0	0	1
Diabetes mellitus	1	0	0	0	0	0	1
Total	32	11	10	6	6	2	67

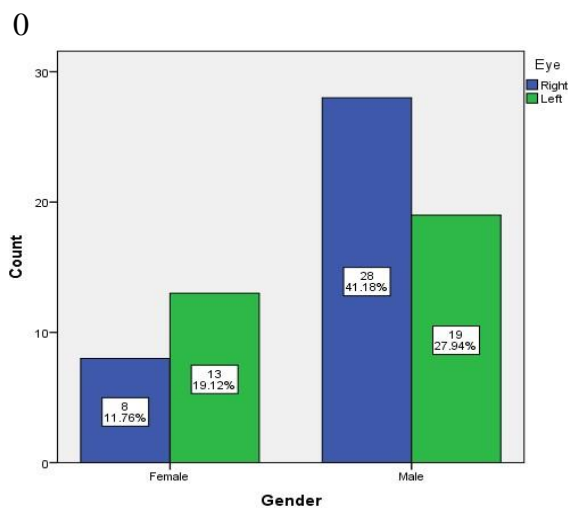


Figure 1: Gender & Eye Distribution in this study (n=68)

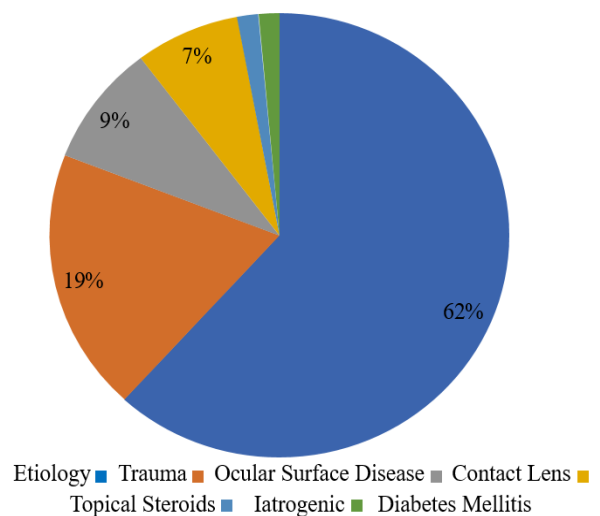


Figure 2: Etiology of Microbial Keratitis (n=68)

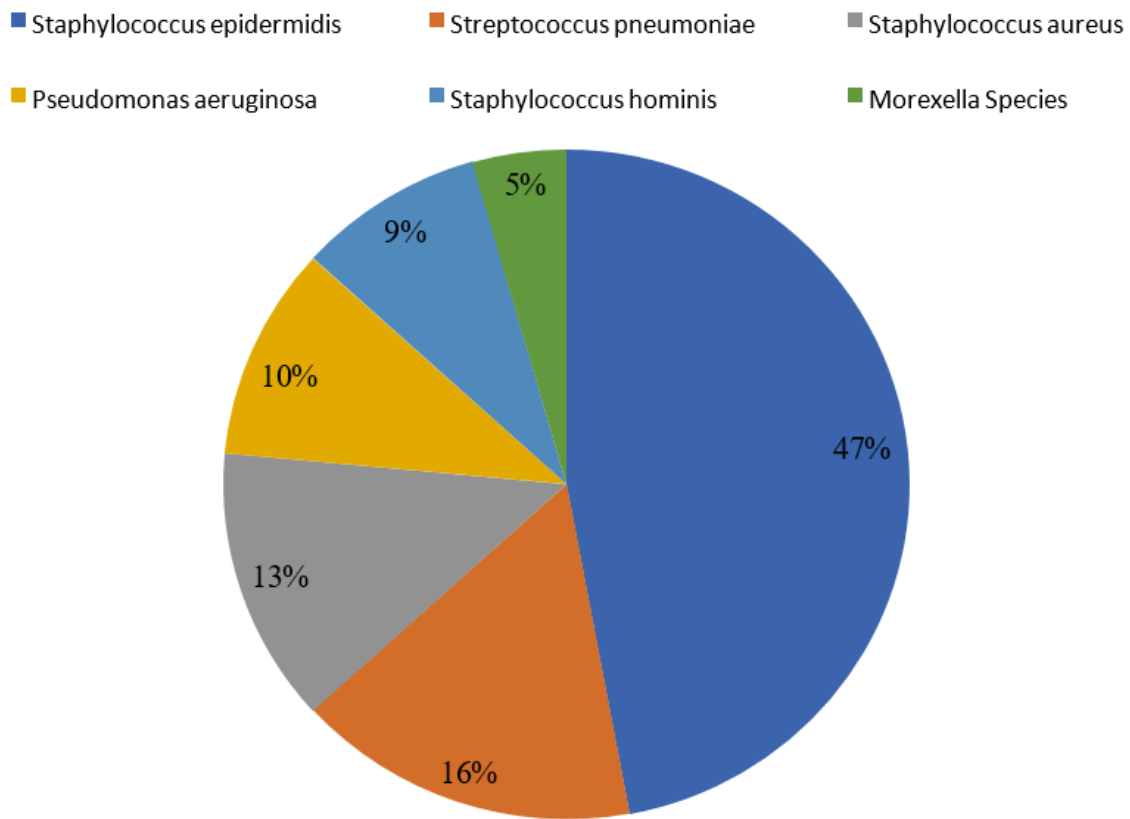


Figure 3: Causative Bacteria of Microbial Keratitis (n=68)

Discussion:

Microbial keratitis, caused by microbial infection, can stem from factors like trauma or contact lens use. Gram-positive bacteria such as *Staphylococcus aureus* and *Streptococcus pneumoniae* are common causes¹³, entering the eye through direct contact or contaminated lenses¹⁴. Early diagnosis and specific treatment are vital for managing this condition and averting severe vision problems¹⁵.

In comparing our study with the study on fungal keratitis in South Asia by Hoffman JJ et al¹⁶, several key differences and similarities emerge. Firstly, while both studies focused on microbial keratitis, our study specifically delved into the etiology and causative bacteria associated with the condition, providing a comprehensive breakdown of the various factors contributing to keratitis cases. Conversely, the referenced study primarily concentrated

on fungal keratitis, offering detailed insights into the clinical and epidemiological features predictive of its microbial etiology in Nepal. Despite these distinctions, both studies underscore the importance of accurate diagnosis and timely treatment in managing keratitis cases effectively.

In comparing our study of 68 patients (mean age 39.93 ± 11.422 years; male 47, female 21) to the study by Kase C et al¹⁷ which consisted of 4047 patients (mean age 47.79 ± 20.68 years; male 53.27%), notable differences and similarities can be observed. Our study focused more on traumatic causes, with 62% attributed to trauma, while the referenced study did not provide specific percentages for trauma-related cases. Both studies identified *Staphylococcus epidermidis* and *Staphylococcus aureus* as prevalent agents, with our study observing *Streptococcus*

pneumoniae as well. However, their study highlighted contact lens use as associated with *Acanthamoeba* spp. (OR = 19.04; $p < 0.001$) and *Pseudomonas* spp. (OR = 3.20; $p < 0.001$), findings not explicitly discussed in ours. These comparisons highlight the need for a comprehensive understanding of corneal infections' epidemiology across different patient populations and risk factors.

There was another similar study conducted by Khor HG et al¹⁸ in tropical climate. Notably, our study included a smaller sample size of 68 patients compared to their 221 cases. Our study revealed a higher mean age of 39.93 years, with a male predominance and a near-equal distribution between right and left eyes. In terms of etiology, trauma was the leading cause in both studies, although the percentages differed significantly, with our study reporting 62% compared to their 49.3%. Conversely, improper contact lens usage was more prevalent in their study at 29.1% versus our 9%. Interestingly, while their study found *Pseudomonas aeruginosa* as the most common bacteria, comprising 49.1% of cases, our study identified *Staphylococcus epidermidis* as the predominant causative agent at 47%. These variations in demographics, etiology, and causative organisms highlight the diverse nature of microbial keratitis presentations and underline the importance of region-specific studies to inform targeted treatment strategies.

If we compare our study of 68 patients with microbial keratitis to a study of 80 pediatric cases by Hepschke JL et al¹⁹, notable differences and similarities are present. Our study had a higher mean age of 39.93 years, with 47% males and 62% of cases attributed to trauma. In contrast, the pediatric study had a mean age of 11 years, with 55% males and trauma causing 24% of cases. Both studies identified contact lens wear as a risk factor, with prevalence at 9% in our study and 26% in the pediatric study. *Staphylococcus epidermidis* was the most common isolate in both studies, at

47% in ours and unspecified in the pediatric study, followed by *Staphylococcus aureus* and *Pseudomonas aeruginosa*. *Streptococcus pneumoniae* was notable in our study at 16%. These findings underscore the importance of age-specific considerations and tailored management approaches in microbial keratitis cases.

Another study, by Lim Wen Siang J et al²⁰ with similar objectives. When comparing our study of 68 patients with this study of 75 eyes in 74 patients, key differences are obvious: This study reports a higher male-to-female ratio of 13.8:1, a mean age of 48 years, and 70% of patients aged 20-59, whereas our study had a mean age of 39.93 years with a more balanced gender distribution. Trauma was the leading cause in our study (62%), while corneal foreign bodies were predominant (56%) in this study, impacting visual outcomes significantly ($P < 0.005$). Both studies highlight Gram-negative bacteria, with *Pseudomonas* species notably prevalent; however, our study noted *Pseudomonas aeruginosa* in 10% of cases, lower than this study's 26.7% with *Pseudomonas* sp. Both studies underscored the correlation between specific bacteria and poor visual outcomes, emphasizing the importance of early intervention strategies.

Pseudophakic cystoid macular edema (PCME) is one of the most common postoperative complications of cataract surgery. As the etiology is multifactorial, the incidence of PCME is variable and ranges from 1-30%¹. Although most of the patients develop subclinical PCME with no effect on vision, some of the patients do develop poor central vision after an uneventful cataract surgery. It is therefore important to identify the risk factors at the time of planning cataract surgery so that appropriate steps can be taken to prevent the occurrence of PCME².

Conclusion:

The study conducted in Mirpur Azad Kashmir provides valuable insights into the

demographics, causes, and bacterial agents responsible for eye infections in the region. It emphasizes the predominance of males in the sample group. The study identifies trauma, ocular surface diseases, and contact lens usage as significant contributors to eye infections, highlighting the need for targeted preventive measures and educational initiatives to promote better eye hygiene practices. The findings regarding the most common causative bacteria underscore the importance of effective treatment strategies tailored to the prevalent microbial agents, aiming to reduce the burden of eye infections and improve ocular health in the community.

References:

1. Sharma N. Microbial Keratitis. Nepalese journal of ophthalmology: a biannual peer reviewed academic journal of the Nepal Ophthalmic Society : NEPJOPH. 2021;13(24):1-2.
2. Harbiyeli İ, Çelebi D. Etiological and Clinical Features of Contact Lens-Associated Microbial Keratitis. 2022;52(5):309-17.
3. Sahay P, Bafna RK, Reddy JC, Vajpayee RB, Sharma N. Complications of laser-assisted in situ keratomileusis. Indian journal of ophthalmology. 2021;69(7):1658-69.
4. Cabrera-Aguas M, Khoo P, Watson SL. Outcomes of Microbial Keratitis Cases Resistant to Antimicrobials in Sydney, Australia. Cornea. 2022;41(5):572-8.
5. Yarımada S, Barut Selver Ö. Comparison of Culture-Positive and -Negative Microbial Keratitis. 2022;52(1):1-5.
6. Kate A, Bagga B, Ramazanov K, Joshi V, Mohamed A, Sharma S. Risk factors, clinical features and outcomes of Neisseria keratitis. International ophthalmology. 2021;41(10):3361-9.
7. Cabrera-Aguas M, Watson SL. Updates in Diagnostic Imaging for Infectious Keratitis: A Review. Diagnostics (Basel, Switzerland). 2023;13(21).
8. Cabrera-Aguas M, Khoo P. Predisposing factors, microbiological features and outcomes of patients with clinical presumed concomitant microbial and herpes simplex keratitis. 2022;36(1):86-94.
9. Sharma B, Soni D. Corticosteroids in the Management of Infectious Keratitis: A Concise Review. 2021;37(8):452-63.
10. Gurnani B, Kaur K. Therapeutic Keratoplasty. StatPearls. Treasure Island (FL) ineligible companies. Disclosure: Kirandeep Kaur declares no relevant financial relationships with ineligible companies.: StatPearls Publishing Copyright © 2024, StatPearls Publishing LLC.; 2024.
11. Khoo P, Cabrera-Aguas MP, Nguyen V, Lahra MM, Watson SL. Microbial keratitis in Sydney, Australia: risk factors, patient outcomes, and seasonal variation. Graefes archive for clinical and experimental ophthalmology = Albrecht von Graefes Archiv für klinische und experimentelle Ophthalmologie. 2020;258(8):1745-55.
12. Koh YY, Sun CC, Hsiao CH. Epidemiology and the Estimated Burden of Microbial
13. Keratitis on the Health Care System in Taiwan: A 14-Year Population-Based Study.
14. American journal of ophthalmology. 2020; 220:152-9.
15. Kusumesh R, Ambastha A, Arya LK, Kumari A, Kumari N, Sinha BP, et al.
16. Epidemiological and microbiological profiles of microbial keratitis in a tertiary eye center in Eastern India (Bihar). Indian journal of ophthalmology. 2023;71(11):3506-12.
17. Fleiszig SMJ, Kroken AR, Nieto V, Grosser MR, Wan SJ, Metruccio MME, et al. Contact lens-related corneal infection: Intrinsic resistance and its compromise. Progress in retinal and eye research. 2020; 76:100804.
18. Alkatan HM, Al-Essa RS. Challenges in the diagnosis of microbial keratitis: A detailed review with update and general

- guidelines. Saudi journal of ophthalmology: official journal of the Saudi Ophthalmological Society. 2019;33(3):268-76.
19. Hoffman JJ, Yadav R. Microbial Keratitis in Nepal: Predicting the Microbial Aetiology from Clinical Features. 2022;8(2).
20. Kase C, Boppré YT, Rocchetti TT, Yu MCZ, Fernandes AG. Microbial keratitis in Sao Paulo, Brazil: a 10-year review of laboratory results, epidemiological features, and risk factors. 2023;87(6): e202200660.
21. Khor HG, Cho I, Lee K, Chieng LL. Spectrum of Microbial Keratitis Encountered in the Tropics. Eye & contact lens. 2020;46(1):17-23.
22. Hepschke JL, Ung L, Cabrera-Aguas M, Ross C, Kumar N, Lahra MM, et al. Pediatric Microbial Keratitis: Experience from Tertiary Referral Centers in New South Wales, Australia. The Pediatric infectious disease journal. 2020;39(10):883-8.
23. Lim Wen Siang J, Wu Zhuan O, Yi Chen N, Sok Lin N. Profile of Microbial Keratitis. Cureus. 2021;13(12): e20663.

Authors Contribution

Concept and Design: Sara Najeeb
Data Collection / Assembly: Nazish Babar
Drafting: Muhammad Irfan Sadiq
Statistical expertise: Muhammad Asif
Critical Revision: Muhammad Usman Sadiq