



**ASJO**

ISSN 3006-2543 (Online)

ISSN 1990-3863 (Print)

# AL-SHIFA JOURNAL OF OPHTHALMOLOGY

An Open Access, Peer Reviewed, Quarterly Journal of  
AL-SHIFA TRUST EYE HOSPITAL

**Vol. 20, No. 2, April – June 2024**

Indexed in

WHO Index Medicus (IMEMR)

Asian Digital Library (ADL)

Pak Medinet

Pakistan Medical and Dental Council IP/033

ISSN 3006-2543 (Online)  
ISSN 1990-3863 (Print)

A  
S  
J  
O

# Al-Shifa Journal of Ophthalmology

---

Vol. 20, No. 2, April – June 2024

---

**QUARTERLY PUBLISHED**

- **Editorial: Implementing Workplace-Based Assessments**
- **Nepafenac Eyedrops After Phacoemulsification**
- **Primary Open Angle Glaucoma and Vitamin D Levels**
- **Etiology and Causative Bacteria of Microbial Keratitis**
- **Lidocaine Application in Cataract Surgery**
- **Surgical Outcomes of Phacoemulsification**

Abstracts available at <https://www.asjoalshifaeye.org> and <http://www.pakmedinet.com/ASJO>  
Manuscript submission through online platform [ejmanager.com](http://ejmanager.com)

---

**Indexed in Index Medicus -EMR**

**Recognized by Pakistan Medical & Dental Council – IP/033**

---

## Al-Shifa Journal of Ophthalmology

Editorial inquiries should be addressed to Prof. Dr. Tayyab Afghani, Department of Orbit and Oculoplastics, Al-Shifa Trust Eye Hospital, Jhelum Road Rawalpindi, Pakistan.  
Tel: 0092 51 5487821-25, Fax: 0092 51 5487827; Email: [aqrcpio@yahoo.com](mailto:aqrcpio@yahoo.com) ;  
Website: [www.asjoalshifaeye.org](http://www.asjoalshifaeye.org)

- Editorial: Implementing Workplace-Based Assessments in Ophthalmology: CPSP's Commendable Endeavor** 46  
Mahmood Ali
- Effect of 0.1% Nepafenac Eye Drops on Macular Thickness After Uneventful Phacoemulsification Assessed by Optical Coherence Tomography** 48  
Anushka Shaukat, Muhammad Azam Khan, Ayisha Shakeel, Irfan Aslam Khattak, Maria Saleem, Huma Zainab
- Primary Open-Angle Glaucoma and Serum Vitamin D Levels** 56  
Masooma Talib, Aqsa Malik, Saima Rasheed, Farah Naz Tahir, Yasir Iqbal Malik, Atteaya Zaman, Anoosh Qayyum, Tehmina Qamar
- Etiology and Causative Bacteria of Microbial Keratitis in Mirpur Azad Kashmir** 61  
Muhammad Asif, Sara Najeeb, Nazish Babar, Muhammad Usman Sadiq, Muhammad Irfan Sadiq, Maliha Ansari
- Effectiveness in Achieving Retrobulbar Infiltrative Anesthesia With and Without Prior Dermal application of Lidocaine on Lids in Cataract Surgery** 68  
Attiqa Riaz, Muhammad Ali, Afifa Ramzan, Saira Shahzadi, Muhammad Hannan Jamil, Memoona Arshad
- Surgical Outcomes of Phacoemulsification at A Tertiary Care Eye Hospital** 75  
Rebecca Murtaz, Sabihuddin Ahmad, Sana Naveed, Inam Ul Haq

# Effect of 0.1% Nepafenac Eye Drops on Macular Thickness After Uneventful Phacoemulsification Assessed By Optical Coherence Tomography

Anushka Shaukat<sup>1</sup>, Muhammad Azam Khan<sup>1</sup>, Ayisha Shakeel<sup>1</sup>, Irfan Aslam Khattak<sup>1</sup>, Maria Saleem<sup>1</sup>, Huma Zainab<sup>2</sup>

## Abstract:

**Objective:** To compare mean macular thickness after uneventful phacoemulsification with 0.1% nepafenac eye drops using optical coherence tomography.

**Methods:** A sample size of 170 patients was calculated using the WHO calculator. Patients were divided into two groups; Group A was given 0.1% nepafenac while Group B was given a placebo. Patients were selected through nonprobability consecutive sampling. Patients were followed after uneventful phacoemulsification. OCT scan of macula was performed preoperatively and on day 7 and day 30. Data was analyzed using SPSS version 24, T-test was applied and a P value <0.05 was considered significant.

**Results:** A total of 170 patients were included in the study with 85 patients in each group. There were 42(24.7%) males in group A and 49(28.8%) in group B and 43(25.3%) females in group A and 36(21.2%) in group B. The mean age of patients in group A was 51.3±6.2 years and 49.8±6.3 years in group B. There was no statistically significant difference in macular thickness of Group A and Group B (215.5±1.0 and 215.6±0.9, p=0.546 respectively) before phacoemulsification surgery. However macular thickness was significantly lower in the nepafenac group, 7 days (220.1±2.4 vs 228.8±4.4, p=0.000) and 30 days postoperatively (217.6±1.6 vs 231.7±6.3, p=0.000).

**Conclusion:** 0.1% Nepafenac is a well-tolerated drug with a significant decrease in macular thickness as compared to placebo following uneventful phacoemulsification. Post-operative use of topical NSAIDs leads to the prevention of cystoid macular edema following cataract surgery. *Al-Shifa Journal of Ophthalmology 2024; 20(2): 48-55. © Al-Shifa Trust Eye Hospital, Rawalpindi, Pakistan.*

1. PAF Hospital, Margalla Road, Sector E9, Islamabad.
2. PAF Hospital Faisal, Shahrah e Faisal, Karachi.

Originally Received: 05 November 2023

Revised: 27 March 2024

Accepted: 28 April 2024

## Correspondence to:

Ayisha Shakeel

PAF Hospital, Margalla Road, Sector E9, Islamabad.

Email: ayisha\_shakeel@yahoo.com

## Introduction:

Pseudophakic cystoid macular edema (PCME) is one of the most common postoperative complications of cataract surgery. As the etiology is multifactorial, the incidence of PCME is variable and ranges from 1-30%<sup>1</sup>. Although most of the patients develop subclinical PCME with no effect on vision, some of the patients do develop poor central vision after an uneventful cataract surgery. It is therefore important to identify the risk factors at the time of planning cataract surgery so that



appropriate steps can be taken to prevent the occurrence of PCME<sup>2</sup>.

The pathogenesis of PCME is unclear and multifactorial. The most probable etiology is the release of inflammatory mediators in anterior and posterior segments because of surgical insult causing blood-aqueous barrier and blood-retinal barrier to break down. This results in the accumulation of eosinophilic exudates within the retinal layers causing cystoid edema<sup>3</sup>. Certain risk factors are associated with developing PCME. The most common ones are surgical complications, Diabetes mellitus, uveitis, and use of prostaglandin analogs in glaucoma<sup>4-6</sup>.

Several drugs have been used to prevent the occurrence of PCME after cataract surgery. Topical nonsteroidal anti-inflammatory drugs (NSAIDs) and corticosteroids have been used alone or in combination, to prevent and treat postoperative cystoid macular edema (CME). Corticosteroids inhibit the phospholipase A2 in the inflammatory cascade reducing the arachidonic acid production whereas the NSAIDs block the cyclooxygenases in the inflammatory cascade which blocks the production of prostaglandins<sup>7</sup>. Nepafenac, Bromfenac, and ketorolac are the NSAIDs that have been used to prevent PCME. Nepafenac has been used to prevent and treat PCME and its efficacy has been established<sup>8</sup>. Similarly, Bromfenac and Ketorolac have also shown promising results in the treatment of PCME<sup>9,10</sup>. However, there are a few studies that show no significant reduction in macular edema with the use of ketorolac and nepafenac<sup>11,12</sup>.

The purpose of conducting our research was to find a solution to varying opinions about the use of NSAIDs in preventing PCME. We selected Nepafenac 0.1% for its ease of availability and comparatively lower cost in the pharmaceutical markets of Islamabad. The objective of this study is to compare the mean difference of macular thickness in patients using Nepafenac and Placebo using optical coherence

tomography after uneventful phacoemulsification (Fig 1).

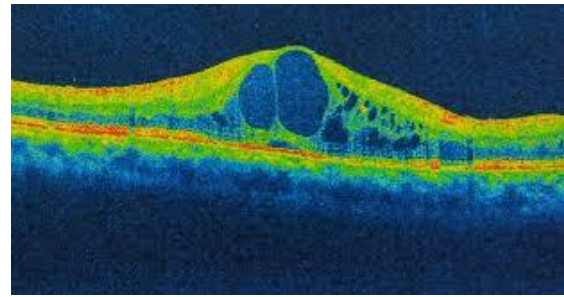


Figure 1: Cystoid Macular Edema

### **Material and Methods:**

We performed a randomized controlled trial in the Department of Ophthalmology, PAF Hospital, Islamabad from 20<sup>th</sup> June 2022 to 20<sup>th</sup> December 2022. Ethical approval was obtained from the ethics review committee of the Institute. The study was conducted on a sample of 170 eyes which was calculated by the WHO sample calculator.

In this study, all male and female patients between the ages of 40 to 65 who were planned to have phacoemulsification with intraocular lens implantation were included. Patients with glaucoma, uveitis, retinal diseases, corneal diseases, epiphora, adnexal diseases, and systemic diseases like diabetes mellitus, hypertension, lung diseases, and cardiovascular diseases were excluded from the study. Also, patients with congenital anomalies of the eye and pregnant and lactating mothers were excluded from the study. Patients who initially were included in the study but had complicated phacoemulsification or prolonged surgery (more than 30 minutes) were also excluded.

After obtaining ethical approval, patients were selected through nonprobability consecutive sampling. Informed consent was taken from all the participants. A detailed history with a complete ophthalmic examination including visual acuity measurement, refraction (subjective and objective), slit lamp examination, tonometry, and fundus examination was performed. Patients underwent uneventful phacoemulsification with intraocular lens

implantation by a single experienced surgeon. Patients were divided randomly using computer computer-generated random number table. Group A was given 0.1% nepafenac topical drops three times a day while group B was given a combination of polyvinyl alcohol 1.4% and Povidone 0.6% (Placebo) with the same frequency. Both drugs were given for 30 days. Optical coherence tomography was performed before cataract surgery and after 7 and 30 days of cataract surgery. Image acquisition was done, and a macular thickness map was taken. The retinal thickness/volume was recorded after image capture to analyze the macular retinal thickness. Macular thickness in both groups was compared before phacoemulsification, and then 7 and 30 days after the surgery. Data was collected and analysed through SPSS version 24. The quantitative variables like age and macular thickness were presented as mean and SD. The qualitative

variables like gender, anatomical sides, and refractive error involved were presented as frequency and percentage. Mean macular thickness was compared in two groups by independent T-test. A p-value of  $\leq 0.05$  was taken as significant. Data was categorized for age, gender, anatomical side, and refractive error. Post-stratification, an independent sample t-test was applied for each stratum.

### Results:

A total of 170 patients were included in the study with 85 in each group. Overall, there were 91(53.5%) male and 79(46.5%) female in our study. The mean age of patients in group A was  $51.3 \pm 6.2$  years and in group B was  $49.8 \pm 6.3$  years. Mean post-operative visual acuity in group A was  $0.7 \pm 0.09$  Log Mar and in group B  $0.75 \pm 0.10$  Log Mar as shown in Table 1.

Table 1: Demographic distribution

Group-wise distribution	Group A (nepafenac)	Group B (placebo group)	Total Number (N=170)
<b>Gender</b>			
Male	42(24.7%)	49(28.8%)	91(53.5%)
Female	43(25.3%)	36(21.2%)	79 (46.5%)
<b>Age category</b>			
40-50 years	43(25.3%)	39(22.9%)	82 (48.2%)
51-65 years	42(24.7%)	46(27.1%)	88 (51.8%)
<b>Anatomical side</b>			
Left	32(18.8%)	29(17.1%)	61 (35.9%)
Right	53(31.2%)	56(32.9%)	109 (64.1%)
<b>Refractive error</b>			
Myopia	7(4.1%)	0(0%)	7 (4.1%)
Hypermetropia	42(24.7%)	43(25.3%)	85 (50%)
Astigmatism	36(21.2%)	42(24.7%)	78 (45.9%)
<b>Descriptive Statistics</b>			
Mean Age (Years)	$51.3 \pm 6.2$	$49.8 \pm 6.3$	
Post-op visual acuity (Log	$0.7 \pm 0.09$	$0.75 \pm 0.10$	

There was no statistically significant difference in macular thickness of Group A and Group B before surgery ( $215.5 \pm 1.0$  and  $215.6 \pm 0.9$ ,  $p=0.546$ ) respectively. However macular thickness was significantly lower

in the nepafenac group after 7 days ( $220.1 \pm 2.4$  vs  $228.8 \pm 4.4$ ,  $p=0.000$ ) and 30 days postoperatively ( $217.6 \pm 1.6$  vs  $231.7 \pm 6.3$ ,  $p=0.000$ ) as shown in table 2.

Table 2: Comparison of macular thickness before surgery, 7 days, and 30 days after surgery

Macular thickness( $\mu\text{m}$ )	Group A (Nepafenac group) N=85	Group B (Placebo group) N=85	P value
Before surgery	215.5 $\pm$ 1.0	215.6 $\pm$ 0.9	0.546
After 7 days of surgery	220.1 $\pm$ 2.4	228.8 $\pm$ 4.4	0.000
After 30 days of surgery	217.6 $\pm$ 1.6	231.7 $\pm$ 6.3	0.000

Table 3: Stratification of macular thickness concerning gender

Gender	Groups	Macular thickness before surgery	P value	Macular thickness after 7 days of surgery	P value	Macular thickness after 30 days of surgery	P value
Male	Group A	214.3 $\pm$ 0.8	0.336	220.3 $\pm$ 2.4	0.444	217.2 $\pm$ 1.6	0.399
	Group B	215.3 $\pm$ 0.8		221 $\pm$ 2.5		220 $\pm$ 2.0	
Female	Group A	216.9 $\pm$ 0.9	0.339	221.3 $\pm$ 2.5	0.468	221.3 $\pm$ 2.5	0.432
	Group B	216.3 $\pm$ 0.9		219.3 $\pm$ 2.3		219.3 $\pm$ 2.3	

Table 4: Stratification of macular thickness in both groups concerning age

Age	Groups	Macular thickness before surgery	P value	Macular thickness after 7 days of surgery	P value	Macular thickness After 30 days of surgery	P value
40-50 years	Group A	214.2 $\pm$ 0.8	0.336	221.3 $\pm$ 2.4	0.444	218.2 $\pm$ 1.5	0.399
	Group B	215.1 $\pm$ 0.8		220.2 $\pm$ 2.5		220 $\pm$ 2.0	
51-65 years	Group A	215.9 $\pm$ 0.8	0.339	220.3 $\pm$ 2.5	0.468	220.3 $\pm$ 2.5	0.432
	Group B	216.3 $\pm$ 0.9		221.3 $\pm$ 2.3		219.2 $\pm$ 2.3	

Table 5: Stratification of macular thickness in both groups concerning anatomical side

Anatomical side	Groups	Macular thickness before surgery	P value	Macular thickness after 7 days of surgery	P value	Macular thickness after 30 days of surgery	P value
Left	Group A	215.3±0.8	0.334	222.5±2.4	0.445	216.2±1.5	0.399
	Group B	215.1±0.8		220.2±2.5		219±2.0	
Right	Group A	215.9±0.8	0.339	221.7±2.5	0.467	221.3±2.5	0.431
	Group B	216.3±0.9		221.3±2.3		219.2±2.3	

Table 6: Stratification of macular thickness in both groups concerning refractive error

Refractive error	Groups	Macular thickness before surgery	P value	Macular thickness after 7 days of	P value	Macular thickness after 30 days of	P value
Myopia	Group A	215.3±0.8	0.334	222.5±2.4	0.445	216.2±1.5	0.399
	Group B	216.1±0.9		220.2±2.5		219±2.0	
Hypermetropia	Group A	219.2.9±0.8	0.339	221.7±2.5	0.467	221.3±2.5	0.431
	Group B	219.3±0.9		221.3±2.3		219.2±2.3	
Astigmatism	Group A	218.5±0.7	0.389	220.1±2.1	0.421	216.2±0.9	0.511
	Group B	217.2±0.7		221.2±2.2		219.1±0.8	

No statistically significant difference was found among macular thickness in both groups concerning gender, age, anatomical side and refractive error with p value >0.05.

### Discussion:

PCME is a common cause of visual impairment after cataract surgery. Optical coherence tomography (OCT) has changed the way retinal diseases are seen and treated nowadays<sup>13,14</sup>. Most clinical trials have analyzed OCT measurements of macular thickness, including studies of CME after cataract

surgery<sup>15</sup>. In the current study, there was no statistically significant difference in macular thickness of Group A and Group B (215.5±1.0 and 215.6±0.9, p=0.546) before surgery. However macular thickness is significantly lower in the nepafenac group 7 days after surgery (220.1±2.4 vs 228.8±4.4, p=0.000) and 30 days postoperatively (217.6±1.6 vs 231.7±6.3, p=0.000). This result corroborates with that of Tzelikis et al, who studied the use of NSAIDs prophylactically after uncomplicated cataract surgery. His study showed that incidence of macular edema



was significantly low in the group receiving Nepafenac compared with placebo<sup>11</sup>. This is similar to the results we achieved in our study.

On the other hand, a randomized study of 162 patients by Almeida et al produced different results. In this study there were three groups with 54 patients in each group. One group received 0.5% ketorolac eyedrops, the other received 0.1% nepafenac eye drops and the third group received placebo. The study found out that there was no statistically significant difference among the three groups in terms of macular thickness. In this study, all of the patients used the medication topically, starting on the day of phacoemulsification (preoperatively) and continuing with its use for 4 weeks<sup>12</sup>. Although there was a trend toward significance in both the nepafenac and ketorolac groups, statistical significance could not be found. The results of this study were different than ours due to a comparatively smaller sample size in each of the groups compared to our study which had a much larger sample size.

Our study has produced similar results to two other studies by Hariparsad et al and an earlier study by Almeida et al. Both these studies suggested that use of topical nepafenac prophylactically is useful for preventing CME after cataract surgery. Furthermore, the use of 0.5% ketorolac tromethamine effectively decreased postoperative macular edema<sup>8,9</sup>. Both these studies showed a statistically significant decrease in macular thickness after the use of NSAIDs which is similar to our study. Another study by Miyake et al also produced similar results. The study confirmed CME using fluorescein angiography, compared two groups of patients using nepafenac and fluorometholone postoperatively, and found that the incidence of CME was significantly lower in the nepafenac group ( $p < 0.0001$ ) during both the second ( $p = 0.0266$ ) and fifth ( $p = 0.0055$ ) weeks<sup>16</sup>. A similar result was found in the study by

McCafferty et al. The study concluded that the use of Nepafenac reduces the risk of PCME in patients with pre-op risk factors but has no benefit in patients with no risk factors. He therefore recommended that Nepafenac may not be used in patients with pre-op risks only rather than in all uneventful cataract surgeries<sup>17</sup>. Wittpenn et al studied the effect of Ketorolac with topical steroids in low-risk patients and found that the addition of Ketorolac significantly reduces the chances of developing PCME in low-risk patients<sup>18</sup>.

A review article by Schalnus et al used more sensitive evaluation methods than visual acuity like contrast sensitivity. The study found no statistical difference while using prophylactic treatment of CME. According to the study the use of NSAIDs is not justified in low-risk patients as there is very less increase in macular thickness and loss of contrast sensitivity in routine cataract surgery in low risk patients<sup>19</sup>.

Multiple similar studies have proved the efficacy of NSAIDs in preventing and treating PCME. Gamache et al proved in their study that Nepafenac is not only useful in preventing PCME but also is effective in treating trauma-induced ocular inflammation<sup>20</sup>. Guo et al discussed in detail the management of PCME and emphasized that when combined with topical steroids, topical NSAIDs have a synergistic effect in controlling post-op inflammation<sup>21</sup>. Wolf et al compared the effect of topical steroids alone and when combined with topical Nepafenac on PCME. He also found that the patients who used Nepafenac had a significantly lower incidence of PCME<sup>22</sup>.

A few locally conducted studies also produced similar results. A study conducted by Jahan Zaib et al compared two groups after phacoemulsification. One group was given 0.1 % Nepafenac and the other group was given 1% Prednisolone. Post op central macular thickness was significantly lower in Nepafenac group compared to Prednisolone group<sup>23</sup>. Similarly, another study by Wali Ullah et al compared two

groups after phacoemulsification. One group received standard treatment whereas other group received additional 0.1 % Nepafenac along with the standard treatment. The group receiving 0.1 % Nepafenac had statistically significant lower central macular thickness compared to other group<sup>24</sup>.

All the above-mentioned studies validated our results in which the Nepafenac group had a statistically significant lower thickness of macula on OCT postoperatively.

### **Conclusion:**

0.1% Nepafenac is a well-tolerated drug with a significant decrease in macular thickness as compared to placebo following uneventful phacoemulsification. Post-operative use of topical NSAIDs leads to the prevention of central macular edema following cataract surgery. Further trials are required to understand an in-depth analysis of the efficacy of topical NSAIDs regarding retinal thinning.

### **References:**

1. Grzybowski A, Sikorski B, Ascaso F, Huerva V. Pseudophakic cystoid macular edema: update 2016. *CIA*. 2016 Sep; Volume 11:1221–9.
2. Modjtahedi BS, Paschal JF, Batech M, Luong TQ, Fong DS. Perioperative Topical Nonsteroidal Anti-inflammatory Drugs for Macular Edema Prophylaxis Following Cataract Surgery. *American Journal of Ophthalmology*. 2017 Apr;176:174–82.
3. Benitah NR, Arroyo JG. Pseudophakic Cystoid Macular Edema. *International Ophthalmology Clinics*. 2010;50(1):139–53.
4. Cohen SM, Davis A, Cukrowski C. Cystoid macular edema after pars plana vitrectomy for retained lens fragments. *Journal of Cataract and Refractive Surgery*. 2006 Sep;32(9):1521–6.
5. Jiramongkolchai K, Lalezary M, Kim SJ. Influence of previous vitrectomy on incidence of macular oedema after cataract surgery in diabetic eyes. *British Journal of Ophthalmology*. 2011 Apr 1;95(4):524–9.
6. Bélair ML, Kim SJ, Thorne JE, Dunn JP, Kedhar SR, Brown DM, et al. Incidence of Cystoid Macular Edema after Cataract Surgery in Patients with and without Uveitis Using Optical Coherence Tomography. *American Journal of Ophthalmology*. 2009 Jul;148(1):128-135.e2.
7. Shelsta HN, Jampol LM. Pharmacologic therapy of pseudophakic cystoid macular edema: 2010 Update. *Retina*. 2011 Jan;31(1):4–12.
8. Hariprasad S. Treatment of cystoid macular edema with the new-generation NSAID nepafenac 0.1%. *OPHTH*. 2009 Jan;147.
9. Almeida DRP, Johnson D, Hollands H, Smallman D, Baxter S, Eng KT, et al. Effect of prophylactic nonsteroidal anti inflammatory drugs on cystoid macular edema assessed using optical coherence tomography quantification of total macular volume after cataract surgery. *Journal of Cataract and Refractive Surgery*. 2008 Jan;34(1):64–9.
10. Sheppard J. Topical bromfenac for prevention and treatment of cystoid macular edema following cataract surgery: a review. *OPHTH*. 2016 Oct; Volume 10:2099–111.
11. Tzelikis PF, Vieira M, Hida WT, Motta AF, Nakano CT, Nakano EM, et al. Comparison of ketorolac 0.4% and nepafenac 0.1% for the prevention of cystoid macular oedema after phacoemulsification: prospective placebo-controlled randomised study. *Br J Ophthalmol*. 2015 May;99(5):654–8.
12. Almeida DRP, Khan Z, Xing L, Bakar SN, Rahim K, Urton T, et al. Prophylactic nepafenac and ketorolac versus placebo in preventing postoperative macular edema after uneventful phacoemulsification.

- Journal of Cataract and Refractive Surgery. 2012 Sep;38(9):1537–43.
13. Nelson ML, Martidis A. Managing cystoid macular edema after cataract surgery: Current Opinion in Ophthalmology. 2003 Feb;14(1):39–43.
  14. Puliafito CA, Hee MR, Lin CP, Reichel E, Schuman JS, Duker JS, et al. Imaging of Macular Diseases with Optical Coherence Tomography. Ophthalmology. 1995 Feb;102(2):217–29.
  15. Srinivasan VJ, Wojtkowski M, Witkin AJ, Duker JS, Ko TH, Carvalho M, et al. High-Definition and 3-dimensional Imaging of Macular Pathologies with High-speed Ultrahigh-Resolution Optical Coherence Tomography. Ophthalmology. 2006 Nov;113(11):2054-2065.e3.
  16. Miyake K, Ota I, Miyake G, Numaga J. Nepafenac 0.1% versus fluorometholone 0.1% for preventing cystoid macular edema after cataract surgery. Journal of Cataract and Refractive Surgery. 2011 Sep;37(9):1581–8.
  17. McCafferty S, Harris A, Kew C, Kassam T, Lane L, Levine J, et al. Pseudophakic cystoid macular edema prevention and risk factors; prospective study with adjunctive once daily topical nepafenac 0.3% versus placebo. BMC Ophthalmol. 2017 Dec;17(1):16.
  18. Wittpenn JR, Silverstein S, Heier J, Kenyon KR, Hunkeler JD, Earl M. A Randomized, Masked Comparison of Topical Ketorolac 0.4% Plus Steroid vs Steroid Alone in Low-Risk Cataract Surgery Patients. American Journal of Ophthalmology. 2008 Oct;146(4):554-560.e1.
  19. Schalnus R, Schalnus R. Topical Nonsteroidal Anti-Inflammatory Therapy in Ophthalmology. Ophthalmologica. 2003;217(2):89–98.
  20. Gamache DA, Graff G, Brady MT, Spellman JM, Yanni JM. Nepafenac, a unique nonsteroidal prodrug with potential utility in the treatment of trauma-induced ocular inflammation: I. Assessment of anti-inflammatory efficacy. Inflammation. 2000;24(4):357–70.
  21. Guo S, Patel S, Baumrind B, Johnson K, Levinsohn D, Marcus E, et al. Management of pseudophakic cystoid macular edema. Survey of Ophthalmology. 2015 Mar;60(2):123–37.
  22. Wolf EJ, Braunstein A, Shih C, Braunstein RE. Incidence of visually significant pseudophakic macular edema after uneventful phacoemulsification in patients treated with nepafenac. Journal of Cataract and Refractive Surgery. 2007 Sep;33(9):1546–9.
  23. Hafiz Muhammad Jahan Zaib, Nazir F, Khan NA, Khalid A, Khan MI. Comparative Study of Topical Steroids Vs Non-steroidal Anti-Inflammatory Drugs to Control Post-Cataract Surgery Macular Edema: Doi: 10.36351/pjo.v40i1.1578. pak J Ophthalmol [Internet]. 2023 Dec 4 [cited 2024 Apr 15];40(1). Available from: <http://pjo.org.pk/index.php/pjo/article/view/1578>
  24. Wali Ullah, Muhammad Irfan, Shahid Abdur Rauf Khan, Adnan Ghalib, Zia uddin Khalil. Role of topical nepafenac in preventing increase in macular thickness after phacoemulsification. J Postgrad Med Inst. 2021;34(4):253–8.

**Authors Contribution**

Concept and Design: Anushka Shaukat  
 Data Collection / Assembly: Muhammad Azam Khan  
 Drafting: Irfan Aslam Khattak, Maria Saleem  
 Statistical expertise: Maria Saleem, Huma Zainab  
 Critical Revision: Ayisha Shakeel