



**ASJO**

ISSN 3006-2543 (Online)

ISSN 1990-3863 (Print)

# AL-SHIFA JOURNAL OF OPHTHALMOLOGY

An Open Access, Peer Reviewed, Quarterly Journal of  
AL-SHIFA TRUST EYE HOSPITAL

**Vol. 20, No. 1, January – March 2024**

Indexed in

WHO Index Medicus (IMEMR)

Asian Digital Library (ADL)

Pak Medinet

Pakistan Medical and Dental Council IP/033

ISSN 3006-2543 (Online)  
ISSN 1990-3863 (Print)

**A  
S  
J  
O**

# **Al-Shifa Journal of Ophthalmology**

---

**Vol. 20, No. 1, January – March 2024**

---

**QUARTERLY PUBLISHED**

- **Editorial: An Elite Surgeon - Dethroning the Master Surgeon**
- **Conjunctival Bacterial Flora in Medical Students**
- **Eye and Hair Color Association for Forensic Identification**
- **Senile Cataract Induced Changes in Crystalline Lens**
- **Prevalence of Trachoma in Gilgit**
- **Topical Anesthesia for Extra Capsular Cataract Extraction**
- **Persistent High IOP after Vitrectomy (Case Report)**

Abstracts available at <https://www.asjoalshifaeye.org> and <http://www.pakmedinet.com/ASJO>  
Manuscript submission through online platform [ejmanager.com](http://ejmanager.com)

---

**Indexed in Index Medicus -EMR**

---

**Recognized by Pakistan Medical & Dental Council – IP/033**

---

# **Al-Shifa Journal of Ophthalmology**

## **A Journal of Al-Shifa Trust Eye Hospital, Rawalpindi**

### **Aims and Scope:**

The aim and scope of the Al-Shifa Journal of Ophthalmology encompass a broad spectrum within the field of Ophthalmology and Optometry. Our journal is dedicated to publishing high-quality research that advances knowledge, innovation, and understanding in various domains, including but not limited to:

1. Clinical Ophthalmology: Diagnosis, treatment, and management of ocular diseases and conditions.
2. Surgical Ophthalmology: Advancements and techniques in eye surgeries and procedures.
3. Basic Research in Ophthalmology: Studies exploring the fundamental mechanisms underlying ocular health and diseases.
4. Optometry: Vision care, refractive errors, contact lenses, and optometric practice.
5. Ophthalmic Pathology: Investigations into ocular diseases at a cellular and molecular level.
6. Vision Science: Research on vision mechanisms, perception, and related disciplines.
7. Ophthalmic Imaging: Innovations and applications in ocular imaging technologies.
8. Pediatric Ophthalmology: Diagnostics, treatments, and developments in pediatric eye care.
9. Community Ophthalmology: Initiatives, studies, and programs addressing eye health in communities.
10. Public Health and Ophthalmology: Research exploring the broader impact of eye health on public well-being.

## Editorial Team:

- **Prof. Dr. Wajid Ali Khan (Editor-in-Chief)**  
Chief of Medical Services,  
Head of Cornea Department, Al-Shifa Trust Eye Hospital, Rawalpindi
- **Prof. Dr. Tayyab Afghani (Editor)**  
Head of Orbit and Oculoplastic Department, Al-Shifa Trust Eye Hospital, Rawalpindi
- **Prof. Dr. Mahmood Ali (Managing Editor)**  
Glaucoma Department, Al-Shifa Trust Eye Hospital, Rawalpindi
- **Prof. Dr. Ume Sughra (Associate Editor)**  
Director Research, Al-Shifa Trust Eye Hospital, Rawalpindi
- **Dr. Syed Ali Hasan Naqvi (Assistant Editor)**  
Resident Ophthalmology, Pakistan Institute of Ophthalmology, Rawalpindi
- **Ms Mehmona Asgher (Assistant Manager)**  
Editorial and Publication Department, Pakistan Institute of Ophthalmology, Rawalpindi

### Editorial Board

- Prof. Dr. Nadeem Qureshi
- Prof. Dr. Amer Awan
- Prof. Dr. Zafar ul Islam
- Prof. Dr. Sumera Altaf
- Prof. Dr. P S Mahar
- Prof. Dr. Abdul Moqet Khan
- Prof Dr. Mahfooz Hussain
- Prof. Dr. Muhammad Shakaib Anwar
- Dr. Rashid Zia
- Dr. Ashbala Khattak

### Advisory Board Members

- Prof. Dr. Shehzad Naroo, UK
- Dr. Jodbhir Singh Mehta, Singapore
- Dr. Shehzad Mian, USA
- Dr. Umer Mian, USA
- Dr. Qazi Khalid Ali

---

Inquiries or comments regarding the journal may be directed to the editorial board, anonymously if so desired. Addresses of board members may be obtained from the editorial office or official website of Al-Shifa Trust; <https://www.asjoalshifaeye.org>

---

## **Information for Authors**

### **Authorship Criteria**

Al-Shifa Journal of Ophthalmology will consider a right to authorship ONLY when ALL four of the authorship criteria of ICJME are met. These criteria are as follows:

Substantial participation in the research work with a contribution to all stages of research namely, the conception of the research work; the research design itself; or the data collection; data analysis following collection; or data interpretation following analysis; AND

Active contribution to the research manuscript during drafting or its critical revision with reference to the importance of the intellectual content; AND Active contribution/participation in the final approval final copy of the manuscript that is ready for publication; AND Willingness to share responsibility for the whole research work to allow for investigation and resolution of integrity and accuracy of research work.

### **Acknowledgment Criteria**

The contribution/effort of all contributors whose participation in the research work doesn't fulfill the above-mentioned conditions can be acknowledged in a separate section towards the end of the manuscript. Examples of such contributors include, but are not limited to:

Those who helped acquire funds for research

Those who supervised the research but did not actively participate

Those who provided help in study design reviewed the manuscript, assisted in the write-up of the manuscript, proofread it for the authors, provided editorial support for technical and language matters, etc.

Colleagues who helped in finding cases for the research, assistance in laboratory procedures, etc.

Statisticians who helped in the analysis of collected data by application of proper statistical tests

### **Addition to the List of Authors**

The ASJO doesn't allow addition, alteration, or deletion in the list of authors which was submitted to the journal at the time of initial submission.

### **Statement of Contributions**

The manuscript submission policy of ASJO requires that the original manuscript be accompanied by a description of individual contributions by each other at the time of initial submission. For this purpose, to facilitate the authors, an Author's undertaking and contributions form has been made available for download on the journal's web page.

### **Corresponding Author**

Al-Shifa Journal of Ophthalmology will communicate with the author designated as the corresponding author during the submission process who is expected to cooperate with the journal for data requests or any additional information that may be required during or after the publication of the manuscript. Therefore, the corresponding author should provide a working email address to be able to answer any queries from the editorial board regarding the manuscript throughout the submission and the peer-review process after the initial submission. Additionally, the corresponding author is expected to reply to all critiques and queries following the publication of a research manuscript.



### **Authors Who Have Deceased Before Publication of The Research**

The use of a death dagger (†) is recommended to notify the death of authors who died before the research was published. The death dagger (†) should be placed immediately after their names and the information about their death and the date of death be provided in a footnote.

### **Instructions for Journal Sections**

Manuscripts are accepted for consideration if neither the article nor any of its contents have been or will be published or submitted elsewhere before appearing in the Al-Shifa Journal of Ophthalmology. Authors have to create an account with the ASJO before they submit their manuscripts.

Authors are required to submit an undertaking signed by all the authors, (certifying originality of work and that the article has not been or will not be published elsewhere, and transfer of copyrights to ASJO). No more than 6 names will be listed under the title; other names will appear in a footnote.

Names and affiliations of authors should not be mentioned in the main file containing the manuscript names, affiliation and complete data of the author(s) should be given during the online submission process.

“Ethical Approval” of the studies and “Authors Undertaking and Contribution Form” need to be uploaded as supplementary files during the online submission process.

Research and Publication Ethics: The authors must declare approval of the ‘Research Ethics Committee’ and clearly mention any ‘Conflict of Interest’ either in the script or attached document.

**Abstracts:** Abstracts should not exceed more than 250 words. This abstract should be structured under the following headings: Objectives, Methods, Results, Conclusion and Keywords. They should briefly describe, respectively, the problem being addressed in the study, how the study was performed, the salient results, and what the authors conclude from the results. Keywords: Three to 10 keywords or short phrases should be added to the bottom of the abstract page. Please use terms from the Medical Subject Headings (MeSH) of Index Medicus.

### **Original Article:**

The original article should be structured under the following headings: Introduction, Material & Methods, Results, Discussion, Conclusions, Acknowledgments, and References. The font style should be “Times New Roman” with font size 12 for body and 14 for headings. There should be spacing of 1.5 between text.

### **Case Report:**

Short reports of cases, clinical experience, drug trials, or adverse effects may be submitted. They must not exceed 1500-2000 words, 15 bibliographic references, and one table or illustration. The report must contain genuinely new information. The format is Title, Abstract, Introduction, Case Report, Discussion, and References.

Review Articles, Editorial, Special Communication, Short Communication, and Pictorial can also be submitted. All these should be submitted along with brief abstracts not exceeding 250 words

References should all start on a separate page.

**References:** The total number of references in an Original Article must not exceed 40, while in the Review Articles maximum limit of references is 100. References must be written single-spaced and numbered as they are cited in the text. The references must be written in Vancouver style. The style for all types of references is given in the ‘Uniform requirements for manuscripts

submitted to biomedical journals (PDF)’. List all authors when they are six or fewer. If they are seven or more, list the first six followed by et al. Following are examples of reference citations:

**Journal Article:** Mansoor H, Khan SA, Afghani T, Assir MZ, Ali M, Khan WA. Utility of teleconsultation in accessing eye care in a developing country during COVID-19 pandemic. PLoS One. 2021 Jan 14;16(1):e0245343.

**Books:** Duke- Elder S, and Leigh AG: Diseases of the Outer Eye. Cornea and Sclera. In Duke-Elder S (ed): System of Ophthalmology, Vol. 8, Part 2. St. Louis C.V. Mosby Company, 1965, pp.110-114. (Recheck publisher, City, etc.).

**Tables and Illustrations:** Tables/Figures should be added to the main file containing the manuscript. Each Table/Figure should have a proper title. Figures should be professionally designed. Symbols, lettering, and numbering should be clear and large enough to remain legible after the figure has been reduced to fit the width of a single column of 3 inches (7.62 cm). Figure 1 (Haq, Afghani, and Qadir). Right eye. Histologic section of tumor, spindle-B type malignant epithelioid cells at the right upper corner, (Hematoxyline and eosin x 400).

**TABLES:** should be typed DOUBLE-SPACED, with NOTHING underlined TRIPLE-CHECK all numbers and percentages. If photographs of patients are used, either the subjects should not be identifiable or their pictures must be accompanied by written permission to publish the picture. Duplication of results given in tables and figures must be avoided. A maximum of 4-6 Tables/Figures can be included in the manuscript.

**Units of Measurement:** All measurements should be expressed in conventional units, with System International (SI) units given in parentheses throughout the text.

**Abbreviations:** Except for units of measurement, abbreviations are discouraged. The first time an abbreviation appears it should be preceded by the words for which it stands, However, the title and abstract must not contain any abbreviations.

**Names of Drugs:** Brand names of drugs are not permitted. Only generic names of drugs should be used.

**Permissions:** Materials taken from other sources must be accompanied by a written statement from both author and publisher giving permission to the Journal for reproduction.

**Review and Processing:** An acknowledgment is issued on receipt of the manuscript. The manuscripts are examined by the editors and then sent for peer review. The comments of reviewers are then conveyed to the corresponding author. After correction/amendments by the authors, an acceptance letter for the accepted article is issued, and the article is placed in the queue for printing. Before publishing the manuscript online, the “Final Proof” is sent to the correspondence email address for approval.

**Publication Fee:** The journal does not charge for submission and processing of the manuscripts.

Al-Shifa Journal of Ophthalmology accepts manuscript submissions through [ejmanager.com](http://ejmanager.com) online submission platform. For submission of manuscripts authors should register an account using the link <http://www.ejmanager.com/my/ajo/>

## Al-Shifa Journal of Ophthalmology

Editorial inquiries should be addressed to Prof. Dr. Tayyab Afghani, Department of Orbit and Oculoplastics, Al-Shifa Trust Eye Hospital, Jhelum Road Rawalpindi, Pakistan.  
Tel: 0092 51 5487821-25, Fax: 0092 51 5487827; Email: [aqrcpio@yahoo.com](mailto:aqrcpio@yahoo.com) ;  
Website: [www.asjoalshifaeye.org](http://www.asjoalshifaeye.org)

- Editorial: An Elite Surgeon - Dethroning the Master Surgeon** 7  
Rashid Zia
- Bacterial Flora of Conjunctiva in Medical Students of Mohtarma Benazir Bhutto Shaheed Medical College Mirpur Azad Kashmir** 9  
Muhammad Usman Sadiq, Sara Najeeb, Umair Tariq Mirza, Fatima Akbar Shah, Muhammad Irfan Sadiq, Nazish Babar
- Beyond the Colors: Exploring the Association between Eye Color and Hair Color for Forensic Identification** 15  
Zulfiqar Ali Buzdar
- Analysis Of Senile Cataract Induced Anatomical/Histo-Pathological And Biochemical Changes In Human Crystalline Lens** 21  
Raja Faisal Zulfiqar, Raheela Adil, Syed Liaquat Ali, Adeel Zafar, Yousuf Khoso, Zen ul Abideen
- Prevalence of Trachoma in Gilgit, Pakistan: A Cross-Sectional Study at Tertiary Care Center** 27  
Qaim Ali Khan , Muhammad Tahir, Yasir Iqbal , Nauroz Fatima, Qurat ul Ain Ghazanfar, Benish Ali
- A Novel Approach – Extra-capsular Cataract Extraction under Topical Anesthesia** 33  
Muhammad Sharjeel, Hafiza Sadia Imtiaz, Muhammad Awais Ashraf, Muhammad Rizwan Khan, Irfan Ullah
- Persistent High Intraocular Pressure (IOP) After Phaco Vitrectomy In a Case of Ocular Trauma** 40  
Xianxin Gao, Rong Zhao, Guohua Wang, Xiaonian Liu



## An Elite Surgeon - Dethroning the Master Surgeon

Rashid Zia<sup>1</sup>

1. *Locum Consultant in Complex Adult Glaucoma – East Kent Hospitals University, UK*

Recently at a conference I was introduced to a term, “Elite Performance” by Professor Peter Shah, the past president of the UK and Eire Glaucoma society. The concept challenged the effectiveness of my current surgical standards. I was forced to reflect on my proud expertise of “under five minutes” phacoemulsification procedure with an audited, unadjusted complication rate of 0.3%.

In the 1980s, Allen Newell, a famous Carnegie Mellon cognitive scientist, analysed reaction times for a variety of tasks reported in learning experiments and he noted that the time taken to perform a task decreases with the number of repetitions of that task. This is termed as “*power law of learning*”.

Acquiring surgical expertise is time consuming to the doctor. If a surgeon doesn't get many learning opportunities, he may never reach that optimal-performance plateau accessible only after repetitive learning has happened.

Traditionally, emphasis has always been placed on the value of comprehensive knowledge, surgical technique, and good manual dexterity as one of the key factors influencing any surgeon's intraoperative performance. However, another set of complementary skills called “non-technical skills” have also been integrated into surgeon's repertoire to optimize surgical performance e.g. familiarity with the instruments and modern technology, ideal room temperature and lighting, background noise, familiarity and relationships with the surgical team, stress, performance anxiety, fatigue, dehydration, and age.

Professor Shah discussed the importance of softer nontechnical skills for elite performance but then went on to challenge

the very crux of surgical training – i.e. “Practice Makes Perfect”. He emphasized, “Practice only makes surgeons' habits permanent”. He added that perfection comes from the time and effort spent in the preparation of anticipating and facing every possible complication of a stressful situation. For example, a master surgeon facing fluid and/or aqueous misdirection during cataract surgery may be slick enough to finish IOL implantation and safely complete the surgery without typical complications. An elite surgeon on the other hand with comparable surgical skills would have anticipated it preoperatively, prepared himself, the patient and his team for such eventualities and more importantly would have also taken steps to prevent fluid misdirection from occurring in the first instance e.g. operating under GA with reduced end tidal volume of carbon dioxide, use of IV mannitol, closed chamber surgical technique, correct use of OVD and a comprehensive plan to reverse aqueous misdirection per-op and postoperatively in all variable possibilities. Hence, a talented surgeon but with poor focus on acquiring non-technical skills is merely a reflection of repetitive poor habits. A situationally aware surgeon who engages into continuous cycle of monitoring and reevaluating performance of his team and himself is able to take dynamic clinical and non-clinical decisions while a stressful event is unfolding. An elite performance surgeon is open to the opinions of others and learns to integrate effective communication in a stressful situation. Surgeon's non-technical skills enable him to improve the functioning of the surgical team and to enhance the patient safety. His leadership qualities ensure a calm and

collected atmosphere promoting a culture of supporting the team for enhanced clinical efficiency and patient safety.

In the end, it is extremely important to pay special attention to frequently ignored but vital performance shaping factors. Physical and psychological health can adversely affect surgeon's performance. Hence to maintain elite performance, it is pertinent to address physical illnesses, mental stress and fatigue. Surgeons may find their

performance decline while battling with negative emotions. Micronutritional deficiencies, poor hydration, lack of physical exercise and mental stress also leads to inflammation of fascia which has demonstrated shortening of telomeres thus exponentially hastening ageing changes.

An experienced surgeon may be praised for his superior surgical skills, but an "elite performance" surgeon is born only when he learns to embrace non-technical skills.

# Bacterial Flora of Conjunctiva in Medical Students of Mohtarma Benazir Bhutto Shaheed Medical College Mirpur Azad Kashmir

Muhammad Usman Sadiq<sup>1</sup>, Sara Najeeb<sup>1</sup>, Umair Tariq Mirza<sup>1</sup>, Fatima Akbar Shah<sup>1</sup>, Muhammad Irfan Sadiq<sup>2</sup>, Nazish Babar<sup>3</sup>

## Abstract:

**Objectives:** To determine the bacterial conjunctival flora present among medical students of Mohtarma Benazir Bhutto Shaheed Medical College, Mirpur, Azad Kashmir

**Methodology:** A microbiological analysis on 196 conjunctival swabs from 196 students with healthy eyes was carried out in this prospective, cross-sectional study conducted at the Divisional Headquarters Hospital, Mirpur, Azad Kashmir. These swabs were used to inoculate blood agar and chocolate agar plates for culture.

**Results:** The study included a total of 196 students. The mean age was  $21.26 \pm 1.555$  years. Of the 196 participants, 131 (66.8%) were males and 65 (33.2%) were females. The number of right and left eyes were 100 and 96, respectively. Only 86 (43.88%) specimens showed growth while the remaining 110 (56.12%) showed no growth. 76 (88%) of the 86 positive isolates were Gram Positive Bacteria. The most common bacteria were *Staphylococcus epidermidis* (67%), followed by *Staphylococcus aureus* (6%). There were only 10 (12%) gram-negative bacteria found in the positive isolates. With 1% of the total, the three most often isolated species were *Citrobacter freundii*, *Burkholderia cepacia*, and *Pseudomonas aeruginosa*.

**Conclusion:** The most common isolated bacteria from the conjunctiva were gram positive bacteria, with *Staphylococcus epidermidis* being the most common. *Al-Shifa Journal of Ophthalmology* 2024; 20(1): 9-14. © Al-Shifa Trust Eye Hospital, Rawalpindi, Pakistan.

- 
1. Mohi-ud-Din Islamic Medical College, Mirpur AJK.
  2. Mohtarma Benazir Bhutto Shaheed Medical College, Mirpur AJK.
  3. Department of Pathology, Gajju Khan Medical College, Swabi.
- 

Originally Received: 05 February 2024

Revised: 2 April 2024

Accepted: 9 April 2024

## Correspondence to:

Muhammad Usman Sadiq  
Mohi-ud-Din Islamic Medical College,  
Mirpur AJK.  
u\_sadiq@hotmail.com

## Introduction:

The mucous membrane that lines the inside of the eyelids and continues to the orbital globe is known as the conjunctiva<sup>1</sup>, and the area between the palpebral and bulbar conjunctiva is known as the conjunctival sac. The conjunctival sac is continuously exposed to the external environment, allowing for the detection of both possible pathogens and normal commensal flora<sup>2</sup>. By taking up potential pathogen colonization sites, generating antimicrobial compounds, or inducing an immune response that shields the host from infection, the typical commensal flora can defend the host<sup>3</sup>. On the other hand, endophthalmitis may result from accidental or surgical penetrating injuries that encourage the migration of local bacterial flora into the eye<sup>4</sup>.

Although a very tiny percentage of people have sterile conjunctival sacs, they are present in the conjunctival sac from birth and throughout life<sup>5</sup>. Numerous organisms, both pathogens and non-pathogens, have been cultured from the normal conjunctiva, but their numbers are typically modest<sup>6</sup>. This results from frequent blinking, which cleanses the conjunctiva every few seconds and mechanically wash away foreign objects, including bacteria<sup>7</sup>. Bacteriostatic agents such as lysozyme, IgA, and IgG, as well as exposure, a moderate blood supply, and a dropped conjunctival temperature brought on by tears evaporating all work to prevent the growth of germs<sup>8</sup>. Excessive usage of antibiotics has been linked to alterations in both pathogenic and normal flora types<sup>9</sup>.

However, due to differences in genetic makeup, age, gender, race, and geography, the range of these microorganisms varies in different individuals<sup>10</sup>. There are various studies which were carried out in different regions to evaluate the normal flora of human conjunctiva<sup>11, 12</sup>.

This research aims to characterize the bacterial flora of the conjunctiva in medical students at Mohtarma Benazir Bhutto Shaheed Medical College in Mirpur, Azad Kashmir, as such data is lacking according to the best of our knowledge.

### **Materials and Methods:**

The study aimed to investigate different bacteria identified as typical conjunctival flora by analyzing 196 conjunctival swabs from 196 students with healthy eyes. The research was conducted as a prospective cross-sectional study at Divisional Headquarters Hospital, Mirpur Azad Kashmir after taking ethical approval, from 1st January 2022 to 30th June 2022. Participant consent was taken before inclusion in the study. Inclusion criteria comprised all registered medical students who provided consent and were free from clinical ocular infections, while individuals with existing eye infections or those undergoing topical antibiotic treatment

were excluded from the study. The conjunctival swabs were collected by the same ophthalmologist to maintain consistency. The specimens were taken from the lower conjunctival sac without a topical anesthetic. Using a cotton swab, the lower lid was pushed to reveal the lower conjunctival fornix. A sterile swab dampened with normal saline was used to gently wipe the lower fornix conjunctiva from the medial to the lateral side after requesting each individual to look upward. To prevent contacting the lid margins, the participants were instructed not to blink during the process. The specimens were streaked onto blood and chocolate agar plates right away, and they were then incubated for a period 24 to 48 hours at 37 °C. Using particular biochemical assays, the species of bacteria were identified. Results were documented by a microbiologist on a pre-designed proforma. Data were analyzed using SPSS version 21.0. Numerical variables like age were expressed as mean and standard deviation. Categorical variables like gender, eye involved, class & isolated bacteria were expressed as frequency and percentages.

### **Results:**

A total of 196 students were included in this study. 31 students from 1<sup>st</sup> year, 36 from 2<sup>nd</sup> year, 34 from 3<sup>rd</sup> year, 41 from 4<sup>th</sup> year, and 54 students participated from final year. The mean age of patients included in this study was 21.26±1.555 years (Table 1). There were more males as compared to females as shown in Figure 1. There were 100 right and 96 left eyes from which the sample was taken.

Out of 196 samples, only 86 (43.88%) showed growth while the remaining 110 (56.12%) showed no growth (Figure 2). Out of 86 positive isolates, 76 (88%) were gram-positive bacteria. *Staphylococcus epidermidis* (67%), followed by *Staphylococcus aureus* (6%), were the most prevalent bacteria. Only 10 (12%) of the positive isolates had gram-negative bacteria. *Citrobacter freundii*, *Burkholderia*

cepacia, and Pseudomonas aeruginosa were the three most frequently isolated species, accounting for 1% each of the total gram-

negatives. Table 2 displays the list of microorganisms that were isolated from the conjunctival sac.

Table 1: Mean age in the study (n=196)

Mean Age in the Study (Years)			
Mean	Std. Deviation	Maximum	Minimum
21.26	1.555	25	17

Table 2: Bacterial Isolates from Conjunctiva of students (n=86)

Bacteria	No of Isolates	Percentage
Gram Positive	76	88%
Staphylococcus epidermidis	58	67%
Staphylococcus aureus	5	6%
Corynebacterium species	5	6%
Others	8	9%
Gram Negative	10	12%
Citrobacter freundii	1	1%
Burkholderia cepacia	1	1%
Pseudomonas aeruginosa	1	1%
Others	7	9%

Figure 1: Gender Distribution in this study (n=196)

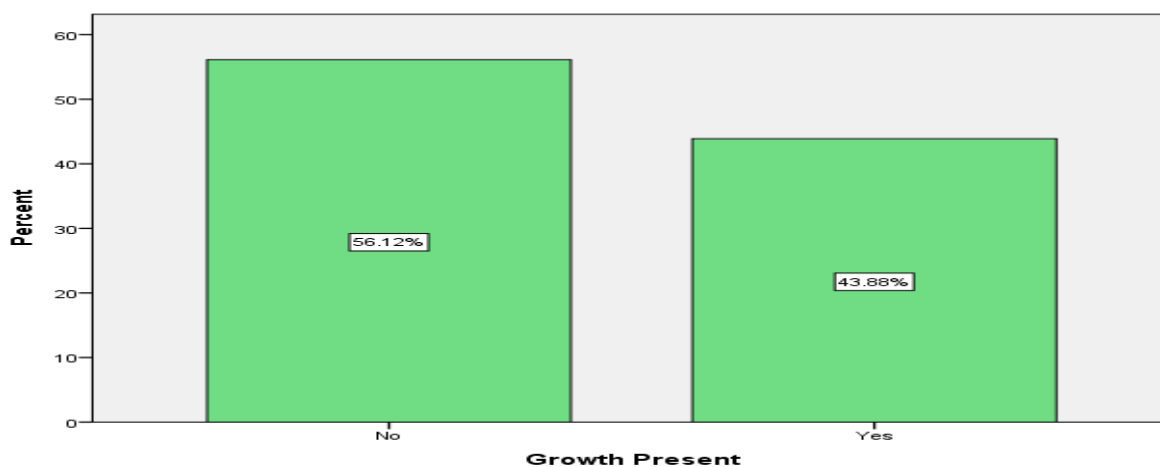
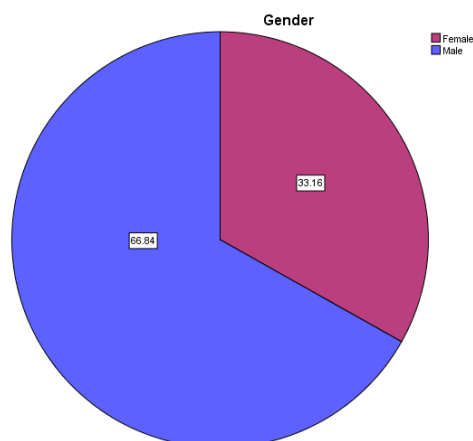


Figure 2: Growth Present in Samples after culture (n=196)

## Discussion:

The normal flora of the conjunctiva refers to the diverse microorganisms that typically inhabit the surface of the eye<sup>13</sup>, specifically the conjunctiva, which is the thin, transparent membrane covering the sclera and inner eyelids<sup>14</sup>. These microorganisms, primarily bacteria, play a crucial role in maintaining ocular health by forming a protective barrier against potential pathogens<sup>15</sup>. Common bacterial species found in the conjunctival flora include *Staphylococcus epidermidis*, *Streptococcus pneumoniae*, and *Corynebacterium* species<sup>16</sup>.

Xu S et al<sup>17</sup> conducted a similar study to determine the bacteriological profile of conjunctiva bacterial Flora in Northeast China. The two studies diverge notably in participant demographics, with our study focusing on a younger cohort (mean age 21.26 years) and having more male participants, whereas this study involved older participants (mean age 60.73 years) with a majority of females. Both studies observed positive culture rates, with our study reporting a rate of 43.88% and this study reporting a higher rate of 48.20%. While both studies identified *Staphylococcus epidermidis* as the most prevalent bacterium, their percentages slightly differed. This study delved into seasonal variations and gender disparities in positive culture rates, along with discussing characteristics like education, employment status, and hypertension, which were not addressed in our study. These comparisons highlight the diverse contexts and findings across different studies in the field.

In another study by Jiang M<sup>18</sup>, analysis of conjunctival sac flora and drug susceptibility was done in normal children in East China. Our study focused on 196 students with a mean age of 21.26 years and found a higher proportion of Gram-positive bacteria (88%) among positive isolates, primarily *Staphylococcus epidermidis* (67%). In contrast, this study included 2516

children, with Gram-positive cocci (91.54%) dominating, led by *Staphylococcus epidermidis* (52.12%) and *Streptococcus* (12.09%). Gender distribution varied, with our study having more males, while this study initially had more males but a slightly higher concordance rate of binocular flora in females. Drug susceptibility profiles were not included in our study. Overall, there were discrepancies in sample sizes, age demographics, microbial prevalence, and drug susceptibility between the two studies. Owji N<sup>19</sup> in his study focused on 72 operated eyes and normal fellow eyes, reporting higher bacterial growth rates in operated eyes (66.7%) compared to normal fellow eyes (43.1%), with nasal specimens showing growth in 90.3% of patients. These results are different from our study as we excluded those individuals who have undergone any treatment.

Adukwu BU<sup>20</sup> in his study determined the conjunctival fungal flora in a tertiary eye hospital in Nigeria. Our study focused on 196 young students, revealing a mean age of 21.26 years and a predominance of Gram-positive bacteria, particularly *Staphylococcus epidermidis*. In contrast, this study involved 225 patients with a broader age range (mean age 41 years) and a nearly equal gender distribution. While our study showed 43.88% growth with notable eye distribution data, this study had a 27.6% culture-positive rate, highlighting *Aspergillus* and *Candida* as common organisms and emphasizing the impact of age groups and occupations on culture results.

Toribio A<sup>21</sup> in his study evaluated the microbiological spectrum of Conjunctival flora in anophthalmic patients. Our study focused on 196 students, predominantly male, aged around 21 years, and found a growth rate of 43.88% with *Staphylococcus epidermidis* being the most prevalent bacterium among positive isolates. In contrast, this study involves 251 isolates from healthy eyes and those with



prostheses, noting *Staphylococcus epidermidis* as the most common organism but also identifying coagulase-positive *Staphylococci*, *Streptococci*, and Gram-negative bacteria. While our study lacks antibiotic sensitivity data, this study reveals no significant differences in sensitivities between isolates from sockets and healthy eyes, but notes increased resistance in Gram-positive microorganisms in subjects using self-prescribed antibiotic drops. Overall, the larger sample size and broader scope of eye conditions in the other study provide a more comprehensive understanding of ocular microbiology and antibiotic resistance patterns.

### Conclusion:

This study showed that gram-positive bacteria, especially *Staphylococcus epidermidis*, are the most prevalent bacteria found in the conjunctiva. This finding highlights the microbial landscape among medical students in the region. Further research may delve into specific factors influencing bacterial prevalence and antimicrobial resistance patterns, aiding in tailored interventions for improved public health outcomes.

### References:

1. Kim S, Lee S, Chang H, Kim M, Kim MJ, Kim KH. In vivo fluorescence imaging of conjunctival goblet cells. *Scientific reports*. 2019;9(1):15457.
2. Wang Z, Zhang P, Huang C, Guo Y, Dong X, Li X. Conjunctival sac bacterial culture of patients using levofloxacin eye drops before cataract surgery: a real-world, retrospective study. 2022;22(1):328.
3. Suzuki T, Sutani T, Nakai H, Shirahige K, Kinoshita S. The Microbiome of the Meibum and Ocular Surface in Healthy Subjects. *Investigative ophthalmology & visual science*. 2020;61(2):18.
4. Simina DS, Larisa I, Otilia C, Ana Cristina G, Liliana MV, Aurelian MG. The ocular surface bacterial contamination and its management in the prophylaxis of post cataract surgery endophthalmitis. *Romanian journal of ophthalmology*. 2021;65(1):2-9.
5. Ke R, Zhang M, Zhou Q, Yang Y, Shen R, Huang H, et al. Bacteriological profiles and drug susceptibility of *Streptococcus* isolated from conjunctival sac of healthy children. *BMC pediatrics*. 2020;20(1):306.
6. Petrillo F, Petrillo A, Marrapodi M. Characterization and Comparison of Ocular Surface Microbiome in Newborns. 2022;10(7).
7. McMonnies CW. The clinical and experimental significance of blinking behavior. *Journal of optometry*. 2020;13(2):74-80.
8. Pflugfelder SC, Stern ME. Biological functions of tear film. *Experimental eye research*. 2020;197:108115.
9. Aramă V. Topical antibiotic therapy in eye infections - myths and certainties in the era of bacterial resistance to antibiotics. *Romanian journal of ophthalmology*. 2020;64(3):245-60.
10. Chiang MC, Chern E. Ocular surface microbiota: Ophthalmic infectious disease and probiotics. *Frontiers in microbiology*. 2022;13:952473.
11. Ramani K, Kaliaperumal S, Sarkar S, Sistla S. Study of Conjunctival Microbial Flora in Patients of Intensive Care Unit. *Korean journal of ophthalmology : KJO*. 2021;35(4):318-24.
12. Peter VG, Morandi SC, Herzog EL, Zinkernagel MS, Zysset-Burri DC. Investigating the Ocular Surface Microbiome: What Can It Tell Us? 2023;17:259-71.
13. Mohamed YH, Toizumi M, Uematsu M, Nguyen HT, Le LT, Takegata M, et al. Prevalence of *Streptococcus pneumoniae* in conjunctival flora and association with nasopharyngeal carriage among children in a Vietnamese community. *Scientific reports*. 2021;11(1):337.
14. Gipson IK. Goblet cells of the conjunctiva: A review of recent

- findings. Progress in retinal and eye research. 2016;54:49-63.
15. Zysset-Burri DC, Schlegel I, Lincke JB, Jaggi D, Keller I, Heller M, et al. Understanding the Interactions Between the Ocular Surface Microbiome and the Tear Proteome. Investigative ophthalmology & visual science. 2021;62(10):8.
  16. Doan T, Akileswaran L, Andersen D, Johnson B, Ko N, Shrestha A, et al. Paucibacterial Microbiome and Resident DNA Virome of the Healthy Conjunctiva. Investigative ophthalmology & visual science. 2016;57(13):5116-26.
  17. Xu S, Zhang H. Bacteriological profile of conjunctiva bacterial Flora in Northeast China: a hospital-based study. 2022;22(1):223.
  18. Jiang M, Zhang J, Wan X, Ding Y, Xie F. Conjunctival sac flora and drug susceptibility analysis in normal children in East China. BMC ophthalmology. 2023;23(1):248.
  19. wji N, Zareifard A. Bacterial Flora of the Conjunctiva One Year after Dacryocystorhinostomy. Middle East African journal of ophthalmology. 2018;25(1):35-9.
  20. Adukwu BU, Nwosu SNN, Emele FE, Uba-Obiano C, Onyiaorah AA. Conjunctival Fungal Flora in a Tertiary Eye Hospital in Nigeria. Journal of the West African College of Surgeons. 2023;13(1):79-83.
  21. Toribio A, Marrodán T, Fernández-Natal I, Martínez-Blanco H, Rodríguez-Aparicio L, Ferrero M. Conjunctival flora in anophthalmic patients: microbiological spectrum and antibiotic sensitivity. International journal of ophthalmology. 2019;12(5):765-73.

**Authors Contribution**

Concept and Design: Sara Najeeb  
Data Collection / Assembly: Umair Tariq Mirza, Fatima Akbar Shah  
Drafting: Muhammad Irfan Sadiq  
Statistical expertise: Nazish Babar  
Critical Revision: Muhammad Usman Sadiq

# Beyond the Colors: Exploring the Association between Eye Color and Hair Color for Forensic Identification

Zulfiqar Ali Buzdar<sup>1</sup>

## Abstract:

**Objectives:** This study aimed to investigate the association between eye color and hair color within the local population of Pakistan for forensic identification purposes.

**Methodology:** Data on eye color and hair color were collected from 293 MBBS students at Sahara Medical College Narowal over three academic years (2021-2023). Data were collected using a questionnaire, with data on specific colors of hair and eyes, and analyzed. Statistical tests including the chi-square test, were conducted to assess the association between eye color and hair color.

**Results:** The findings revealed a statistically significant relationship between eye color and hair color (p value <0.01). Brown and black hair colors were predominant among the study population, while brown and black eyes were the most common eye colors. The association between these phenotypic traits has practical implications for forensic identification, highlighting their importance as distinctive markers of individual identity.

**Conclusion:** The association between eye color and hair color underscores their potential utility for forensic identification purposes. Integrating information on these phenotypic traits into forensic investigations can enhance the accuracy and reliability of identification techniques, contributing to the administration of justice. *Al-Shifa Journal of Ophthalmology* 2024; 20(1): 15-20. © Al-Shifa Trust Eye Hospital, Rawalpindi, Pakistan.

---

1. Department of Forensic Medicine and Toxicology, Sahara Medical College Narowal.

---

Originally Received: 13 February 2024

Revised: 2 April 2024

Accepted: 8 April 2024

## Correspondence to:

Zulfiqar Ali Buzdar

Department of Forensic Medicine and Toxicology, Sahara Medical College Narowal

forensicatitsbest@gmail.com

## Introduction:

Forensic identification plays a pivotal role in criminal investigations providing crucial evidence for identifying individuals involved in various legal proceedings<sup>1</sup>. In the history of forensic science, anthropometry proposed by Alphonse Bertillon in the late 19th century stands as a landmark method for individual identification. Central to Bertillon's system were physical measurements of various body parts but equally essential were distinctive features such as eye color and hair color<sup>2</sup>. For ages, these were considered the sole choices until the traditional methods of identification such as fingerprinting and DNA analysis have long been employed by forensic scientists and investigators<sup>1,3</sup>. However, now advancements in genetic analysis techniques have opened new avenues for forensic identification, including the

exploration of phenotypic traits such as eye color and hair color<sup>4</sup>.

Eye color, a phenotypic trait determined by the amount of melanin in the iris is influenced by complex genetic factors. Variations in genes such as HECT domain and RCC1-like domain-containing protein 2 (HERC2) and ocular albinism (OCA2) have been associated with different but most prominent eye colors for identification purposes including green, brown, and black<sup>5</sup>. Similarly, hair color is determined by the presence and abundance of melanin in the hair follicles with variations in genes related to melanin production contributing to differences in hair color including blond, brown, and black making it valuable for forensic identification<sup>6,7</sup>.

The association between eye color and hair color has attracted interest in forensic medicine due to its potential implications for establishing individuality based on physical characteristics<sup>8</sup>. By examining the relationship between these two phenotypic traits forensic scientists aim to explore associations to develop more accurate methods for identifying individuals from forensic evidence<sup>9</sup>.

However, despite the potential significance of the association between eye color and hair color for forensic identification, relatively few studies have systematically investigated this relationship, particularly within specific populations relevant to current ethnic origin. Therefore, the present study aims to fill this gap by examining the association between eye color and hair color among of Pakistani population.

Unknown individuals are brought for medicolegal and postmortem examination very frequently to the Department of Forensic Medicine. Establishing identification always remains to be the first task by the medical personnel<sup>10</sup>. By elucidating the relationship between eye color and hair color in this population, the research seeks to contribute valuable insights to the field of forensic medicine, potentially enhancing forensic

identification techniques and advancing our understanding of the genetic basis of phenotypic traits<sup>11</sup>. Ultimately, the findings of this study may have implications for forensic investigations assisting medical personnel and law enforcement agencies in the accurate identification of individuals involved in criminal activities<sup>12</sup>.

### **Materials and methods:**

The study received approval from the Institutional Review Board (IRB) to ensure compliance with ethical standards. A cross-sectional descriptive study design was adopted to explore the association between eye color and hair color for forensic identification. After getting informed consent, the students were invited to participate.

A non-probability convenient sampling technique was employed for participant selection. The study population comprised 293 third year MBBS students enrolled at Sahara Medical College Narowal over three academic years (2021-2023), consisting of 106 males and 187 females. Data on eye color and hair color were collected from each participant through a standardized pre-tested questionnaire. Participants self-reported their eye color categorized as green, brown, or black, and hair color categorized as blond, brown, or black.

Statistical analysis was conducted to assess the association between eye color and hair color. Chi-square tests were used to determine the strength and significance of the association with a p-value <0.05.

### **Results:**

The study was conducted on 293 research participants, with 106 males and 187 females included in the study. The mean age of the individuals in the study was  $20.94 \pm 0.76$ .

Table 1 displays the frequency and percentage distribution of different eye colors among study participants. The eye colors included in the table are green, brown, and black the most predominant eye colors observed in Pakistan. The study in

the table 01 revealed that the brown eyes were the most prevalent accounting for 161 students which constitutes 54.9% of the total sample. While the black eyes were found to be the second most common with 128 students making up 43.7% of the total sample. The green eyes were accounted to be the least common, with only 4 students representing 1.4% of the total sample. To simplify the participants under study in the sample had predominantly brown or black eyes while green eyes are significantly less common.

Table 2 presents the frequency and percentage distribution of different hair colors among research participants in this study. The hair colors studied in this research were categorized as blond, brown, and black. Black hair was the most prevalent with 216 cases constituting 73.7% of the total sample amounting to almost 3/4<sup>th</sup> of the population under study. The brown hair was found to be the second most common with 75 cases under study making up 25.6% of the total sample. The blond hair was analyzed to be the least common with only 2 cases, representing 0.7% of the total sample.

Table 3 presents the association between eye color and hair color among a total of 293 participants by applying chi square test of association. It displays the frequency

distribution of different combinations of eye and hair colors. Among cases with green eyes there were 2 individuals with brown hair and 2 individuals with black hair with a final total of just 4 cases. For individuals with brown eyes, there was just 1 case with blond hair, 57 cases with brown hair, and 103 cases with black hair totaling for accumulation of 161 students. Among those with black eyes, there was just 1 case of blond hair, 16 cases with brown hair, and 111 cases with black hair making a total of 128 students in this category. The totals for each hair color category indicate that there are 2 individuals with blond hair, 75 individuals with brown hair and 216 individuals with black hair among the entire sample. These numbers highlight the distribution of hair colors within each eye color category, providing prevalence aspect ratio into the association between these two characteristics among the individuals under the study.

The p-value <0.01 in the association between eye color and hair color highlights the level of statistical significance of the observed relationship. In this context, a p-value <0.01 indicates that the association between eye color and hair color is statistically significant at the chosen level of significance.

*Table 1: Frequency Distribution of Eye Color*

Eye Color	Frequency	Percent	Valid Percent
Green	4	1.4	1.4
Brown	161	54.9	54.9
Black	128	43.7	43.7
Total	293	100.0	100.0

*Table 2: Frequency Distribution of Hair Color*

Hair Color	Frequency	Percent	Valid Percent
Blond	2	0.7	0.7
Brown	75	25.6	25.6
Black	216	73.7	73.7
Total	293	100.0	100.0

*Table 3: Association of Eye Color with Hair Color*

Eye Colour	Hair Colour			Total	P value
	Blond	Brown	Black		
Green	0	2	2	4	0.000
Brown	1	57	103	161	
Black	1	16	111	128	
Total	2	75	216	293	

**Discussion:**

The findings of this study provide valuable information into the association between eye color and hair color among third year MBBS students, contributing to the body of knowledge in forensic medicine and toxicology. The results reveal a statistically significant relationship between these two phenotypic traits with a p-value of 0.000 indicating that the observed distribution of eye color and hair color combinations is highly unlikely to have occurred by chance alone.

The predominance of brown and black hair colors among the study population aligns with broader population trends reflecting the prevalence of these hair colors in various ethnic groups. Similarly, the distribution of eye colors with brown and black eyes being more common than green eyes, mirrors patterns observed in diverse populations worldwide<sup>13</sup>. These findings lay immense importance of considering population-specific characteristics when developing forensic identification techniques based on phenotypic traits<sup>14</sup>.

The observed association between eye color and hair color has practical implications for forensic investigations particularly in cases where readily possible traditional methods of identification may be the only choice available<sup>15</sup>. By incorporating information on eye color and hair color into forensic databases and investigative procedures law enforcement agencies can enhance their ability to identify individuals from forensic evidence such as eyewitness descriptions confirmed from DNA samples collected from crime scenes<sup>16</sup>.

Furthermore, the association between eye color and hair color highlights the complex interplay between genetics and phenotypic expression. While specific genes, such as *HERC2* and *OCA2*, have been implicated in determining eye color variations, the genetic basis of hair color is equally multifaceted involving genes related to melanin production and distribution<sup>17</sup>. Future research exploring the genetic underpinnings of these traits may provide further insights into their inheritance patterns and variability across populations<sup>16</sup>.

The study contributes to our understanding of the association between eye color and hair color for forensic identification purposes, highlighting the importance of these phenotypic traits in individual identification<sup>18</sup>. By elucidating the relationship between eye color and hair color among research participants, this research advances our knowledge of forensic medicine domain, paving the way for improved identification techniques and enhancing the capabilities of forensic science in solving crimes and serving justice<sup>19</sup>.

The predominance of brown and black hair colors among the study population along with the distribution of eye colors, underscores the variability and complexity of human phenotypic traits. By analyzing the association between eye color and hair color, this research contributes valuable insights to the field of forensic science, providing a foundation for the development of more accurate and reliable identification techniques<sup>20</sup>.

Practical implications of these findings extend to forensic investigations where eye



color and hair color can serve as valuable descriptors for identifying individuals from forensic evidence. Integrating information on these phenotypic traits into forensic databases and investigative procedures can enhance the efficiency and effectiveness of law enforcement efforts, ultimately contributing to the administration of justice<sup>21</sup>.

Logically, the study investigated the association between eye color and hair color among the local population of Pakistan, shedding light on their potential utility for forensic identification purposes. The findings revealed a statistically significant relationship between these two phenotypic traits emphasizing their importance in individual identification within the context of forensic investigations.

### **Conclusion:**

In conclusion, this study advances our understanding of the association between eye color and hair color for forensic identification purposes underscoring their importance as distinctive markers of individual identity. By bridging the gap between genetics, phenotypic expression, and forensic science this research contributes to the ongoing quest for accurate and reliable methods of individual identification, ultimately serving to uphold the principles of justice and accountability in society.

### **References:**

1. Amankwaa AO, McCartney C. The effectiveness of the current use of forensic DNA in criminal investigations in England and Wales. *Wiley Interdisciplinary Reviews: Forensic Science*. 2021 Nov; 3(6):e1414.
2. Balanovska E, Lukianova E, Kagazezheva J, Maurer A, Leybova N, Agdzhoyan A, Gorin I, Petrushenko V, Zhabagin M, Pylev V, Kostryukova E. Optimizing the genetic prediction of the eye and hair color for North Eurasian populations. *BMC genomics*. 2020 Sep; 21:1-3.
3. Bardan F, Higgins D, Austin JJ. A custom hybridisation enrichment forensic intelligence panel to infer biogeographic ancestry, hair and eye colour, and Y chromosome lineage. *Forensic Science International: Genetics*. 2023 Mar 1; 63:102822.
4. Brancato D, Coniglio E, Bruno F, Agostini V, Saccone S, Federico C. Forensic DNA Phenotyping: Genes and Genetic Variants for Eye Color Prediction. *Genes*. 2023 Aug 10; 14(8):1604.
5. Bulbul O, Zorlu T, Filoglu G. Prediction of human eye colour using highly informative phenotype SNPs (PISNPs). *Australian Journal of Forensic Sciences*. 2020 Jan 2; 52(1):27-37.
6. Chen Y, Branicki W, Walsh S, Nothnagel M, Kayser M, Liu F, VISAGE Consortium. The impact of correlations between pigmentation phenotypes and underlying genotypes on genetic prediction of pigmentation traits. *Forensic Science International: Genetics*. 2021 Jan 1; 50:102395.
7. Dabas P, Jain S, Khajuria H, Nayak BP. Forensic DNA phenotyping: Inferring phenotypic traits from crime scene DNA. *Journal of forensic and legal medicine*. 2022 May 1; 88:102351.
8. Dorgaleleh S, Naghipoor K, Barahouie A, Dastaviz F, Oladnabi M. Molecular and biochemical mechanisms of human iris color: A comprehensive review. *Journal of Cellular Physiology*. 2020 Dec; 235(12):8972-82.
9. Freire-Aradas A, Phillips C, Huidobro VL, Carracedo Á. Phenotypic markers for forensic purposes. *Forensic science and humanitarian action: interacting with the dead and the living*. 2020 Feb 10:457-72.
10. Heuschkel ML, Labudde D. Reconsideration of Bertillonage in the age of digitalisation: Digital anthropometric patterns as a promising

- method for establishing identity. *Forensic Science International: Synergy*. 2023 Dec 27;100452.
11. Hopman R, M'charek A. Facing the unknown suspect: Forensic DNA phenotyping and the oscillation between the individual and the collective. *BioSocieties*. 2020 Sep; 15(3):438-62.
  12. Kahtoon F, Ahmed RM, Iqbal N, Balouch Z, Alenazi FS. Genetic Identification: A Review on Autosomal Single Nucleotide Polymorphism's as Diagnostic Tool for Identifying Human. *Journal of Pharmaceutical Research International*. 2021 Feb 3; 32(46):25-33.
  13. Kayser M, Branicki W, Parson W, Phillips C. Recent advances in Forensic DNA Phenotyping of appearance, ancestry and age. *Forensic Science International: Genetics*. 2023 Apr 6:102870.
  14. Keyes CA, Mahon TJ, Gilbert A. Human Decedent Identification Unit: identifying the deceased at a South African medico-legal mortuary. *International Journal of Legal Medicine*. 2022 Nov; 136(6):1889-96.
  15. M'charek A, Toom V, Jong L. The trouble with race in forensic identification. *Science, Technology, & Human Values*. 2020 Sep; 45(5):804-28.
  16. Sari O I, Simsek SZ, Filoglu G, Bulbul O. Predicting Eye and Hair Color in a Turkish Population Using the HIrisPlex System. *Genes*. 2022 Nov 11;13(11):2094.
  17. Simcoe M, Valdes A, Liu F, Furlotte NA, Evans DM, Hemani G, Ring SM, Smith GD, Duffy DL, Zhu G, Gordon SD. Genome-wide association study in almost 195,000 individuals identifies 50 previously unidentified genetic loci for eye color. *Science Advances*. 2021 Mar 10;7(11):eabd1239.
  18. Stanley UN, Khadija AM, Bukola AT, Precious IO, Davidson EA. Forensic DNA profiling: autosomal short tandem repeat as a prominent marker in crime investigation. *The Malaysian journal of medical sciences: MJMS*. 2020 Jul; 27(4):22.
  19. Tozzo P, Politi C, Delicati A, Gabbin A, Caenazzo L. External visible characteristics prediction through SNPs analysis in the forensic setting: a review. *Frontiers in Bioscience-Landmark*. 2021 Oct 30; 26(10):828-50.
  20. Venkataramanan S, Mathavan S, Parandaman T. A bioinformatic specific platform towards precise estimate of eye colour forensic intelligence using hirisplex. *International Journal of Medical Toxicology & Legal Medicine*. 2020; 23(3and4):101-6.
  21. Walsh S, Kayser M. Prediction of Physical Characteristics, such as Eye, Hair, and Skin Color, Based Solely on DNA. In *Forensic DNA Applications* 2023 Apr 24 (pp. 357-386). CRC Press.

**Authors Contribution**

Concept and Design: Zulfiqar Ali Buzdar  
 Data Collection / Assembly: Zulfiqar Ali Buzdar  
 Drafting: Zulfiqar Ali Buzdar  
 Statistical expertise: Zulfiqar Ali Buzdar  
 Critical Revision: Zulfiqar Ali Buzdar

# Analysis Of Senile Cataract Induced Anatomical/Histo-Pathological And Biochemical Changes In Human Crystalline Lens

Raja Faisal Zulfiqar<sup>1</sup>, Raheela Adil<sup>1</sup>, Syed Liaquat Ali<sup>2</sup>, Adeel Zafar<sup>2</sup>, Yousuf Khoso<sup>3</sup>, Zen ul Abideen<sup>4</sup>

## Abstract:

**Objectives:** To evaluate histopathological & physiological alterations in lenses affected by senile cataracts for a better understanding of the disease.

**Methodology:** After approval from the relevant ethical committee, analysis of 20 lenses removed surgically for Implant of a synthetic lens in patients aged 55 to 70 years was performed by histopathologic techniques using hematoxylin & eosin-stained slides and anatomical micrometric measurements. The duration of the study was approximately six (6) months. Random probability sampling was used.

**Results:** 55% of the crystalline lenses were found to have pathologic calcification, 45% of them showed enlarged or bladder cells, 40% presented with nuclear fibrosis, 20% had ectopic shifting of surface lining epithelial cells underneath the posterior capsule, and finger-like microstructures were seen projecting in the posterior wall of the capsule of the lenses in 15% of lenses.

**Conclusion:** Most of the lenses attributed more than one histopathological finding. A marked decrease in the size of epithelial cells was observed, whereas alterations in the thickness of the lenses were insignificant with a p-value of  $>0.05$ . *Al-Shifa Journal of Ophthalmology 2024; 20(1): 21-26. © Al-Shifa Trust Eye Hospital, Rawalpindi, Pakistan.*

1. RYK Medical College Rahim Yar Khan.
2. Shahida Islam Medical & Dental College, Lodhran.
3. Al-Tibri Medical College, Karachi.
4. CMH Institute of Medical Sciences, Bahawalpur.

Originally Received: 1 March 2024

Revised: 11 April 2024

Accepted: 13 April 2024

## Correspondence to:

Dr. Raja Faisal

RYK Medical College Rahim Yar Khan.

Department of Anatomy.

rajafaisal76@hotmail.com

## Introduction:

Senile cataracts have been identified as one of the commonest cause of visual disturbance and even complete blindness all over the world.<sup>1</sup> Throughout the life eye lens function needs an intact refractive index, biomechanical integrity and transparency.<sup>2</sup> While axial length is generally thought to be the main biometric factor that influences refractive growth, it is also believed that the crystalline lens plays an important part in the emmetropization of the human eye.<sup>3</sup> The lens is one of the most important components of vision and plays an essential role in the adjustment of vision for both near and far as well as in the adaptation of vision in dark and bright environments is crucial for vision.<sup>4</sup> Cataract formation is a degenerative alteration of the lens metabolism. There is a variety of biochemical changes involved in the

formation of a cataract.<sup>5</sup> Cataract formation is accelerated by hyperglycemia due to the excessive production of oxidative stress.<sup>6</sup> A cataract is a discolored or clouded lens. It has several underlying causes and is usually associated with a decrease in optical quality due to a decrease in lens clarity and a change in lens color.<sup>7</sup> Cataracts are most common among middle-aged and older people (>40 years) and the risk of developing them increases with age. Signs and symptoms of a cataract include lens loss, painless vision, blurred vision, and other visual problems that affect both eyes.<sup>8</sup> Many people with other systemic diseases have a higher risk of developing a cataract, such as; cardiovascular disease patients.<sup>9</sup> Cataracts are the leading cause of blindness worldwide. It also causes moderate-severe vision impairment around the world.<sup>10</sup> Senile Cataracts (Age-related Cataract) affects about 17% of the world's population and causes more than half of vision loss and significant disease and economic burden worldwide.<sup>11</sup>

### **Materials and Methods:**

Forty-two (42) patients having senile cataracts who underwent surgery in Sheikh Zayed Hospital over six (6) Months from January 2022 to June 2022, were included. Patients between 55-70 years with senile cataracts were included. Patients with any systemic disease e.g. hepatitis, myocardial infarction, diabetes mellitus, hypertension, or glaucoma, and any history of ocular trauma were excluded.

Twenty-five (25) patients were operated on for intra-capsular cataract-containing lens removal at the ophthalmology department of Sheikh Zayed Hospital Rahim Yar Khan and in addition also donated three (3) lenses as control which were obtained from patients (who fell victim of evisceration) to support our study. Twenty-five (25) senile intra-capsular cataracts were obtained from the Eye Theatre of Sheikh Zayed Hospital Rahim Yar Khan and were processed at once to prevent any histopathological/morphological change.

All the lenses (control, close to normal or with cataract) were fixated in 10% buffered neutral formalin for 24 hours<sup>12</sup>, later cut into equal halves, and fixed in fresh fixative for an additional 30 hours. Then lens tissues were gradually dehydrated in increasing concentration of alcohol from 60% to 100%. Lens Tissues were bathed by xylene and embedded in paraffin. Sections of Three (3) micron were cut by the help of a microtome and for visual accuracy were stained using hematoxylin and eosin H&E and periodic acid Schiff (PAS) stains. Finally, lenses were put under the microscope for histopathological and morphological analysis, particularly focusing on alterations in the capsule, lining surface epithelium, arrangement of fibers, and nucleus of the lens.

### **Results:**

The lenses used as the control presented a normal appearance on thorough observations. They showed absolute transparency, no evidence of angiogenesis, were delicately soft, elasticity was observed and in shape, bi-convexity was observed, and a comparatively flat anterior surface was also observed, all the surfaces were smooth and had an average diameter of 8mm and thickness of 3-4 mm. Lenses with senile cataracts showed opaque yellow to light brownish color, consistency was rigid, had irregular surfaces, and violated diameters.

Figure 1 shows that in transverse sections, the control lens was biconvex, the body surrounded by hardened capsule (A) with the nucleus of the lens placed centrally, separated from behind by posterior capsule covering, while ventrally and at thickest point by sub-capsular single-layered sheet of lining epithelial units, also aligned with ventral cortex which is made up of parallel and meridionally placed layers of lens fibers whose nuclei showed the arched placement named as bow arrangement (B) with elongated nuclei (C)

Insignificant thinning in lens capsule was evident in lenses affected by cataracts in all

planes in comparison to control lenses (Table 1). A significant decrease was observed in the mean diameter of sub-capsular mono-layered flattened epithelial cells ( $9.05 \pm 0.42 \mu\text{m}$ ) ( $p$ -value  $< 0.05$ ) in cataract-affected lenses in comparison to control lenses with a value of ( $12.08 \pm 0.86 \mu\text{m}$ ).


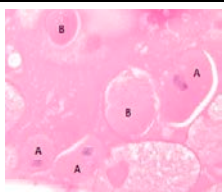
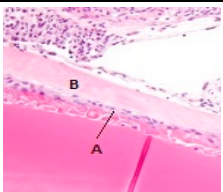
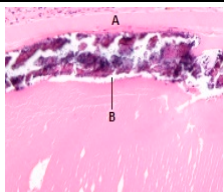
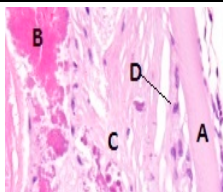
Quality bow arrangement and original lamellar organization of the lens vanished in the cortex of lenses affected by senile cataracts. Many other pathological changes were evident in histopathological slides of cataract-affected lenses (Table 2).

*Table 1: Comparative Analysis of thickness of the capsule ( $\mu\text{m}$ ) and lining epithelial cell span ( $\mu\text{m}$ ) in control vs cataract-containing lenses.*

Capsular regions and cells ( $\mu\text{m}$ )	Control ( $\mu\text{m}$ )	Cataractous lenses ( $\mu\text{m}$ )	P value
Equatorial capsule	$5.18 \pm 0.61$	$5.21 \pm 0.41$	$>0.05$
Posterior capsule	$4.50 \pm 0.76$	$2.38 \pm 0.38$	$>0.05$
Anterior capsule	$7.02 \pm 0.85$	$5.99 \pm 0.88$	$>0.05$
Lining epithelia	$12.01 \pm 0.86$	$9.05 \pm 0.42$	$<0.05$

*Table 2: Histopathological variations in 20 human senile cataract-affected lenses in percentage. (Many lenses possess more than one change)*

Histopathologic Variation	No of lenses	altered morphology %	Patients age (years)	Patients mean age (years)
Villi in the posterior capsule	3	15	65-70	68
Calcification in lens	11	55	60-70	66
Ectopic epithelia	4	20	65-70	67
Nuclear fibrosis	8	40	60-70	67
Enlarged or bladder cell	9	45	55-67	61

				
<b>Figure-1</b> Transverse histological section of the control lens.	<b>Figure-2</b> Bloated lens fibers with pathologically retained nucleus are known as balloon cells (A). Morgagnian globules (B) are roundly shaped, bloated fibers. (H&E stain $\times 400$ , $3\mu\text{m}$ )	<b>Figure-3</b> Subcapsular <u>hyperplasia</u> of the epithelium just under the anterior <u>lens capsule</u> (A). The cataract-affected lens exhibits thickening and of the <u>anterior lens capsule</u> (B) (H&E stain $\times 400$ , $3\mu\text{m}$ )	<b>Figure-4</b> (A) Anterior capsule of the lens. subcapsular deposits of the calcium just under the anterior capsule of the lens (B). (H&E stain $\times 400$ , $3\mu\text{m}$ )	<b>Figure-5</b> Anterior capsule of the lens (A), fragmented, condensed lens fiber material (B), Subcapsular fibrosis (C) and also note hyperplasia of <u>epithelium</u> just under the anterior capsule (D). (H&E stain $\times 400$ , $3\mu\text{m}$ )

**Discussion:**

In our study we found that lens thickness does not change in senile cataracts and similar findings were reported by Lopez and Diez in their study.<sup>13</sup> A significant decrease of  $0.905 \pm 0.42 \mu\text{m}$  was observed in the mean epithelial cells of fourteen (14) cataract-affected lenses range (6 to  $10 \mu\text{m}$ ) when analyzed with similarly aged lenses of normal people having a value of  $12.01 \pm 0.86 \mu\text{m}$  (range 10 to  $14 \mu\text{m}$ ). Identical remarks were presented by Xie et al while studying apoptosis of lens epithelial cells and the possible cause of this change stated by him was decreased metabolic activity in cataract-affected lenses.<sup>14</sup> Balloon cell finding may be related to decreasing metabolic activity with progressing age, Li et al in their work on differently expressed genes associated with deficient lens epithelial cells mentioned similar findings and suggested increasing oxidative stress related to age might be a factor responsible for this via up and down-regulation of certain genes.<sup>15</sup> Finding of Nuclear fibrosis was frequently observed in a significant number of cases, denaturation and coagulation of soluble lens protein could be a potential reason for this pathology, Taiyab et al in their study regarding Understanding the Role of Yes-Associated Protein reported similar findings and concluded that change occurred in Fibrotic cataracts, posterior capsular opacification (PCO), and anterior subcapsular cataracts (ASC) are mainly attributed to the transforming growth factor- $\beta$  (TGF $\beta$ )-induced epithelial-to-mesenchymal transition (EMT) of lens epithelial cells (LECs).<sup>16</sup> While evaluating the calcium deposition on cataract affected lens, it is assumed that a potential reason for this is associated with increased permeability of the lens caused by sluggish metabolism and low energy as a result of increasing age. Chowdhary et al were on the same page as us on the similar finding but in addition, they indicated yet another possible mechanism of Activation of Nrf2/HO-1 Antioxidant Pathway by heme

Attenuates.<sup>17</sup> We found that a significant number of cataract-affected lenses showed the dorsal movement of epithelial cells under the posterior capsule, but we are unaware of the possible pathologic mechanism behind it, mirrored findings had been recorded in a study by Li et al also argued that possibly Arginase-1 promotes lens epithelial-to-mesenchymal transition in different models of anterior subcapsular cataract.<sup>18</sup> Many of the cataract-affected lenses showed more than one pathologic finding. Many of these changes were possibly due to genetic modifications as stated by Kafeel S in 2022.<sup>19</sup> Our study concludes that lack of energy required for normal physiological function of lens with increasing age may be the best assumed reason behind sclerotic and degenerative pathologies of lenses.

**Conclusion:**

Most of the lenses attributed more than one histopathological finding. A marked decrease in the size of epithelial cells was observed, whereas alterations in the thickness of the lenses were insignificant with a p-value of  $>0.05$ .

**References:**

1. Luo J, Chen X, Yang Y, Liu Y, Feng Y, Chen G. Association of MTHFR C667T Polymorphism, Homocysteine, and B Vitamins with Senile Cataract. *J Nutr Sci Vitaminol (Tokyo)*. 2023;69(2):136-144. doi: 10.3177/jnsv.69.136. PMID: 37121723.
2. Cheng C, Parreno J, Nowak RB, Biswas SK, Wang K, Hoshino M, Uesugi K, Yagi N, Moncaster JA, Lo WK, Pierscionek B, Fowler VM. Age-related changes in eye lens biomechanics, morphology, refractive index and transparency. *Aging (Albany NY)*. 2019 Dec 16;11(24):12497-12531. doi: 10.18632/aging.102584. Epub 2019 Dec 16. PMID: 31844034; PMCID: PMC6949082.



3. Chakraborty R, Lacy KD, Tan CC, Park HN, Pardue MT. Refractive index measurement of the mouse crystalline lens using optical coherence tomography. *Exp Eye Res.* 2014 Aug;125:62-70. doi: 10.1016/j.exer.2014.05.015. Epub 2014 Jun 2. PMID: 24939747; PMCID: PMC4121730.
4. Shaheen G, Paul J, Fleischman D. Macrophakia: The characterization of a novel lens condition. *Heliyon.* 2024 Jan 26;10(3):e25161. doi: 10.1016/j.heliyon.2024.e25161. PMID: 38322959; PMCID: PMC10844534.
5. Hegde KR, Henein MG, Varma SD. Establishment of mouse as an animal model for study of diabetic cataracts: biochemical studies. *Diabetes Obes Metab.* 2003 Mar;5(2):113-9. doi: 10.1046/j.1463-1326.2003.00251.x. PMID: 12630936.
6. Kafeel S, Hashim Z, Fawwad A, Nawab SN. Predisposition of SOD1, GPX1, CAT genetic variants and their haplotypes in cataractogenesis of type 2 diabetes mellitus in Pakistan. *Acta Diabetol.* 2022 May;59(5):623-632. doi: 10.1007/s00592-021-01832-5. Epub 2022 Jan 17. PMID: 35037135.
7. He L, Cui Y, Tang X, He S, Yao X, Huang Q, Lei H, Li H, Liao X. Changes in visual function and quality of life in patients with senile cataract following phacoemulsification. *Ann Palliat Med.* 2020 Nov;9(6):3802-3809. doi: 10.21037/apm-20-1709. Epub 2020 Nov 5. PMID: 33183034.
8. Olson RJ, Braga-Mele R, Chen SH, et al. Cataract in the Adult Eye Preferred Practice Pattern®. *Ophthalmology* 2017;124:1-119.
9. Osmanov EM, Manyakov RR, Velichko PB, Zhabina UV, Fabrikantov OL, Nikolashin SI. Rasprostranennost' i vyyavlyaemost' vozrastnoi katarakty pri zabolevaniyakh serdechno-sosudistoi sistemy [Prevalence and detection rate of senile cataract in individuals with cardiovascular diseases]. *Vestn Oftalmol.* 2022;138(4):41-47. Russian. doi: 10.17116/oftalma202213804141. PMID: 36004590.
10. Rewri P, Lohan A, Aggarwal S, Chodhary P, Singhal A. Cataract surgical reach: Falling short to catch white cataracts! *Indian J Ophthalmol.* 2021 Jun;69(6):1575-1578. doi: 10.4103/ijo.IJO\_2560\_20. PMID: 34011744; PMCID: PMC8302299.
11. Yuan S, Wolk A, Larsson SC. Metabolic and lifestyle factors in relation to senile cataract: a Mendelian randomization study. *Sci Rep.* 2022 Jan 10;12(1):409. doi: 10.1038/s41598-021-04515-x. PMID: 35013517; PMCID: PMC8748724.
12. Lee, G. and Luna, H.T. Manual of histologic staining methods of the Armed Forces Institute of Pathology, 3rd edition. New York, Toronto. London and Sydney. McGraw Hill Book Company, 1968.
13. López-de la Rosa, A., Díez-Montero, C., Martínez-Plaza, E. *et al.* Senile Cataract Formation Does Not Affect Crystalline Lens Thickness. *Ophthalmol Ther* 13, 819–830 (2024).
14. Xie Q., Xue L., Cao X., Huang L., Song Y. (2022). Apoptosis of lens epithelial cells and expression of NLRP3-related proteins in patients with diabetes and cataract. *Ocular Immunol. Inflamm.*, 1–8. 10.1080/09273948.2022.2079537.
15. Li H, Gao L, Du J, Ma T, Ye Z, Li Z. Differentially expressed gene profiles and associated ceRNA network in ATG7-Deficient lens epithelial cells under oxidative stress. *Front Genet.* 2022 Dec 7;13:1088943. doi: 10.3389/fgene.2022.1088943. PMID: 36568386; PMCID: PMC9768497.
16. Taiyab A, Belahlou Y, Wong V, Pandi S, Shekhar M, Chidambaranathan GP, West-Mays J. Understanding the Role of Yes-Associated Protein (YAP) Signaling in the Transformation of Lens Epithelial Cells (EMT) and Fibrosis. *Biomolecules.* 2023 Dec

- 9;13(12):1767. doi: 10.3390/biom13121767. PMID: 38136638; PMCID: PMC10741558.
17. Chowdhury A, Balogh E, Ababneh H, Tóth A, Jeney V. Activation of Nrf2/HO-1 Antioxidant Pathway by Heme Attenuates Calcification of Human Lens Epithelial Cells. *Pharmaceuticals (Basel)*. 2022 Apr 19;15(5):493. doi: 10.3390/ph15050493. PMID: 35631320; PMCID: PMC9145770.
18. Li Q, Wang Y, Shi L, Wang Q, Yang G, Deng L, Tian Y, Hua X, Yuan X. Arginase-1 promotes lens epithelial-to-mesenchymal transition in different models of anterior subcapsular cataract. *Cell Commun Signal*. 2023 Sep 18;21(1):236. doi: 10.1186/s12964-023-01210-4. PMID: 37723490; PMCID: PMC10506332.
19. Kafeel S, Fawwad A, Basit A, Nawab SN. Clinical Association of Biochemical Variations Among Multilocus Genotypes of Antioxidant Enzymes with Susceptibility of Cataract in Hyperglycemia. *Appl Biochem Biotechnol*. 2022 Sep;194(9):3871-3889. doi: 10.1007/s12010-022-03957-x. Epub 2022 May 12. PMID: 35556207.

**Authors Contribution**

Concept and Design: Dr. Raja Faisal Zulfiqar  
Data Collection / Assembly: Umair Tariq Mirza, Fatima Akbar Shah  
Drafting: Dr Adeel Zafar, Dr Zen-ul-Abideen  
Statistical expertise: Dr. Syed Liaquat Ali  
Critical Revision: Dr Yousuf Khoso, Dr Raja Faisal Zulfiqar

# Prevalence of Trachoma in Gilgit, Pakistan: A Cross-Sectional Study at Tertiary Care Center (2018-2023)

Qaim Ali Khan<sup>1</sup>, Muhammad Tahir<sup>2</sup>, Yasir Iqbal<sup>3</sup>, Nauroz Fatima<sup>1</sup>, Qurat ul Ain Ghazanfar<sup>4</sup>, Benish Ali<sup>4</sup>

## Abstract:

**Objective:** To assess the prevalence of trachoma among patients attending a tertiary care hospital in Gilgit, Pakistan.

**Methods:** Data for this descriptive cross-sectional study was collected by consecutive sampling from analyzing the medical records of all the patients presenting to the Gilgit Eye Care Centre during the spanning from January 2018 to January 2023 (a 5-year period) ensuring that diagnosis of trachoma was based upon the WHO criteria (FISTO). The data was analyzed according to gender and age on SPSS and results were compiled.

**Results:** A total of 24,589 patients were examined during the study period consisting of 61.8% females and 38.2% males. The estimated prevalence of trachoma was 0.22% (95% confidence interval: 0.14% - 0.30%). Among them, 54 were diagnosed with active trachoma, with mean age 23.30, SD 14.32 years with a female to male ratio of approximately 4.26:1 (81% females, 19% males).

**Conclusion:** This pilot study identified prevalence of trachoma in a hospital setting, highlighting the need for population-based studies to assess the true disease burden in Gilgit. *Al-Shifa Journal of Ophthalmology 2024; 20(1): 27-32. © Al-Shifa Trust Eye Hospital, Rawalpindi, Pakistan.*

- 
1. Azad Jamu Kashmir Medical College, Muzaffarabad.
  2. Combined Military Hospital, Mardan.
  3. Watim Medical College, Rawat Rawalpindi.
  4. Combined Military Hospital, Muzaffarabad.
- 

Originally Received: 15 February 2024

Revised: 03 April 2024

Accepted: 11 April 2024

## Correspondence to:

Yasir Iqbal  
Watim Medical College, Rawat  
Rawalpindi.  
yazeriqbal@gmail.com

## Introduction:

Trachoma, a neglected tropical disease caused by the bacterium *Chlamydia trachomatis*, casts a long shadow on global public health. It remains the leading infectious cause of blindness worldwide, disproportionately impacting low-resource communities.<sup>1</sup> An estimated 1.9 million people globally suffer from vision impairment or blindness due to trachoma<sup>2</sup>, highlighting the devastating consequences of this chronic eye infection. While most infected individuals experience no initial symptoms, repeated infections over extended periods can lead to a progressive and debilitating disease.<sup>3</sup> Untreated trachoma progresses through stages, culminating in trichiasis, a condition where the eyelashes turn inward and scrape against the cornea, causing excruciating pain, corneal scarring, and ultimately, irreversible blindness.<sup>4</sup>

Trachoma remains a significant public health concern across 42 countries.<sup>5</sup> However, stories of success offer hope. Several nations, including Pakistan, have made remarkable strides in tackling the disease. Supported by the World Health Organization's (WHO) initiative, the Global Elimination of Blinding Trachoma by 2020 (GET 2020) program, Pakistan implemented the SAFE strategy (Surgery, Antibiotics, Facial cleanliness, Environmental improvement) with significant impact.<sup>6</sup> This strategy led to a dramatic decrease in active trachoma cases and trichomatous trichiasis, particularly in upper Sindh.<sup>7</sup> While the initial GET 2020 target of global elimination by 2020 was not met, significant progress has been made. Africa, once the most affected continent, has witnessed a 90% reduction in trachoma cases.<sup>8</sup> Renewed global efforts, with a target of elimination by 2030, offer a glimmer of hope for a trachoma-free future. Despite these successes, challenges remain. Population displacement and migration patterns can reintroduce trachoma into previously controlled areas.<sup>9</sup> Furthermore, achieving complete national elimination requires sustained commitment and a well-coordinated national trachoma plan to reach all at-risk populations.<sup>10</sup>

Pakistan's progress in tackling trachoma serves as a testament to the effectiveness of the SAFE strategy and unwavering commitment.<sup>11</sup> However, achieving complete national elimination necessitates continued vigilance. Study<sup>6</sup> across various districts, including D.G. Khan (Punjab), Chitral (Khyber Pakhtunkhwa), and Shahdadkot (Sindh), have documented the presence of trachoma, highlighting the need for geographically specific data to guide targeted interventions. Estimates suggest that roughly 0.81 million people in Pakistan still suffer from trachoma, underlining the importance of ongoing efforts to eliminate this disease.<sup>12</sup>

This pilot study aimed to obtain a preliminary assessment of trachoma prevalence in Gilgit, Pakistan, by

determining the prevalence of trachoma among patients attending a tertiary care hospital in Gilgit. This can serve to evaluate the potential risk in this specific population and set a path for targeted interventions for trachoma elimination.

### **Materials and Methods:**

This descriptive cross-sectional study aimed to determine the prevalence of trachoma in patients presenting to a tertiary care hospital in Gilgit, Pakistan. Following ethical approval from the Gilgit Eye Care Centre's ethical committee, analysis of medical records from January 2018 to January 2023 was conducted using nonprobability consecutive sampling method. Medical records of all patients presenting during this period were reviewed. Patients of all ages were included if their diagnosis aligned with the WHO trachoma classification (follicles [F], inflammation-intense [I], scarring [S], trichiasis [T], opacity [o]). Exclusion criteria encompassed corneal opacities, trichiasis, follicles, or opacities attributable to other ocular diseases. The data was entered on SPSS version 21 for analysis. Descriptive data were presented as frequencies while numerical data as means and standard deviations.

### **Results:**

A cross-sectional study examined a total of 24,589 patients consisting of 61.8% females and 38.2% males. Among them, 54 were diagnosed with active trachoma, with ages ranging from 3 to 70 years (mean 23.30, SD 14.32 years). The estimated prevalence of trachoma was 0.22% (95% confidence interval: 0.14% - 0.30%). Reflecting the female predominance in the overall population, trachoma diagnosis exhibited a female to male ratio of approximately 4.26:1 (81% females, 19% males). The data on active trachoma prevalence by age and sex revealed a distinct distribution. While the overall population leaned female, the analysis of active trachoma cases revealed a surprising

trend. Contrary to the initial statement about a female predominance, the data in the table I shows the highest prevalence (around 33%) in female children under 10 years old. This rate was nearly double that observed in males of the same age group (around 15%). Notably, the prevalence steadily declined with increasing age, with patients over 30 years old demonstrating a significantly lower prevalence (around 7%). In contrast to active trachoma, trachomatous trichiasis (TT) manifested primarily in adults, as expected. Table II highlights the distribution within the 54

active trachoma cases. Interestingly, no cases of TT were identified in children under 10 years old. The first appearance occurs in the 10–15-year age group, affecting only females (1.85%). This pattern continues into the 16–30-year age group, with a low prevalence (3.7%) equally distributed between sexes. A dramatic rise in TT prevalence is observed in those exceeding 30 years old, reaching a very high value (almost 95%) in the table. Here, females are significantly more affected (over 50%) compared to males (around 7%).

*Table 1: Active Trachoma Prevalence by Age and Sex*

Age group (years)	Male (%)	Female (%)	Total (%)
1-9	15.75	33.21	48.96
10-15	11.84	19.1	30.94
16-30	3.45	9.48	12.93
>30	1.49	5.69	7.18
Total	32.53	67.47	100

(n=54)

*Table 2: Trachomatous Trichiasis Prevalence by Age and Sex*

Age Group (years)	Male (%)	Female (%)	Total (%)
1-9	0	0	0
10-15	0	1.85	1.85
16-30	1.85	1.85	3.7
>30	7.4	51.8	94.45
Total	9.25	55.5	100

(n=54)

### **Discussion:**

We estimated a prevalence of active trachoma of 0.22% among the patients in our study. While this represents a relatively low overall burden, a closer look at the data reveals concerning trends regarding age and sex distribution. The study identified the highest prevalence of active trachoma (around 33%) in females under 10 years

old. This finding is surprising as some previous research suggests a higher prevalence in females of reproductive age.<sup>13</sup> Studies conducted in Ethiopia, for instance, documented a higher burden among women aged 1-9 years compared to younger children.<sup>14</sup> One possible explanation for the observed discrepancy in could be differences in hygiene practices

between younger and older girls. Further research is needed to explore the specific factors contributing to the high prevalence in this age group.

The study also found a steady decline in active trachoma prevalence with increasing age. This aligns with observations from other studies<sup>15</sup>, suggesting a potential link between repeated exposure and the development of the more severe stage, trichomatous trichiasis (TT). The absence of TT cases in children under 10 further supports this notion, as TT typically develops over years of chronic infection.

The dramatic rise in TT prevalence observed in those exceeding 30 years old (almost 95%) underscores the long-term consequences of untreated trachoma. This finding is consistent with global data highlighting the disproportionate burden of TT in adults, particularly females.<sup>16</sup>

The female predominance in trachoma diagnosis (around 4.26:1) aligns with previous research.<sup>17</sup> Factors such as close contact with young children, who may be asymptomatic carriers, and increased caregiving responsibilities could contribute to this disparity.<sup>18</sup> However, the reasons behind the higher prevalence of TT in females over 30 require further investigation.

Several factors are believed to contribute to trachoma infection. Studies suggest that the presence of facial flies, large family size, ocular discharge, nasal discharge, and low socioeconomic status all increase the risk of trachoma.<sup>19</sup> Living in high-altitude regions with unsafe water sources is also considered a risk factor. Open defecation is widely recognized as a major risk factor for trachoma transmission.<sup>19</sup> However, some studies suggest that simply having access to a latrine might not be enough.<sup>17</sup> Latrine use is crucial and research indicates that a significant portion of the population may not be using available facilities. Conversely, several practices can help prevent trachoma infection i.e. regularly washing children's faces and clean environment and hygienic waste disposal.<sup>20</sup>

This study offers valuable insight into understanding trachoma in Gilgit. A key strength is the utilization of a standard clinical examination and WHO criteria for diagnosing trachoma. This approach ensures the accuracy and generalizability of the findings within the context of established practices.

This study has several limitations. Firstly, the cross-sectional hospital-based design limits the generalizability of the findings to the entire population of Gilgit. People with existing eye complaints are more likely to seek care at a hospital, potentially biasing the sample towards a higher prevalence than what exists in the general population. Additionally, the study did not investigate the reasons behind the observed higher prevalence in young females. Furthermore, seasonal variations in trachoma prevalence were not considered. Confounding factors such as access to clean water and sanitation, along with socioeconomic status, were not addressed in this study. Obtaining information on these factors through surveys and questionnaires could provide valuable insights into potential risk factors for trachoma.

Despite these limitations, our study indicated the tip of the ice burg and necessitates further investigation for trachoma prevalence in the region. Larger-scale, population-based studies with prospective survey-based clinical examinations are needed to confirm our findings and establish the true regional burden of trachoma. Additionally, employing advanced diagnostic tools like PCR tests could provide a more comprehensive picture of active infections. Furthermore, exploring alternative treatment options and the effectiveness of community-based interventions alongside antibiotics could offer valuable insights for optimizing trachoma control strategies in Gilgit and Pakistan as a whole.

### **Conclusion:**

This pilot study identified prevalence of trachoma in a hospital setting, highlighting

the need for population-based studies to assess the true disease burden in Gilgit.

### References:

1. Martin K. Challenges confronting global public health. *Journal of Moral Theology*. 2021 May 19;1(CTEWC Book Series 1):40-52.
2. Atsbha SG. A review of the prevalence of trachoma, its control program and challenges in Ethiopia. *International Journal of Drug Regulatory Affairs*. 2023;11(1):54-60.
3. Solomon AW, Burton MJ, Gower EW, Harding-Esch EM, Oldenburg CE, Taylor HR, Traoré L. Trachoma (Primer). *Nature Reviews: Disease Primers*. 2022;8(1).
4. Ahmad B, Patel BC. Trachoma. 2023 May 23. StatPearls [Internet]. Treasure Island (FL): StatPearls Publishing. 2023.
5. Debrah O, Mensah EO, Senyonjo L, de Souza DK, Hervie TE, Agyemang D, Bakajika D, Marfo B, Ahorsu F, Wanye S, Bailey R. Elimination of trachoma as a public health problem in Ghana: Providing evidence through a pre-validation survey. *PLoS neglected tropical diseases*. 2017 Dec 12;11(12):e0006099.
6. Khan AA, Florea VV, Hussain A, Jadoon Z, Boisson S, Willis R, Dejene M, Bakhtiari A, Mpyet C, Pavluck AL, Gillani M. Prevalence of Trachoma in Pakistan: results of 42 population-based prevalence surveys from the global trachoma mapping project. *Ophthalmic epidemiology*. 2020 Mar 3;27(2):155-64.
7. Salahuddin T, Nisar MY, Ahmed A, Naseem I. Trachoma in School Going Children at District Bahawalpur, Pakistan: Incidence and Causes. *Review of Education, Administration & Law*. 2018 Dec 31;1(1):33-40.
8. Renneker KK, Abdala M, Addy J, Al-Khatib T, Amer K, Badiane MD, Batcho W, Bella L, Bougouma C, Bucumi V, Chisenga T. Global progress toward the elimination of active trachoma: an analysis of 38 countries. *The Lancet Global Health*. 2022 Apr 1;10(4):e491-500.
9. Sanders AM, Abdalla Z, Elshafie BE, Nute AW, Long EF, Aziz N, Weiss P, Callahan EK, Nash SD. Prevalence of trachoma within refugee camps serving South Sudanese refugees in White Nile State, Sudan: Results from population-based surveys. *PLoS Neglected Tropical Diseases*. 2019 Jun 13;13(6):e0007491.8.
10. Yajima A, Lin Z, Mohamed AJ, Dash AP, Rijal S. Finishing the task of eliminating neglected tropical diseases (NTDs) in WHO South-East Asia Region: promises kept, challenges, and the way forward. *The Lancet Regional Health-Southeast Asia*. 2023 Nov 1;18.
11. World Health Organization. Report of the 21st meeting of the WHO alliance for the global elimination of trachoma by 2020, Geneva, Switzerland, 20-22 April 2017. World Health Organization; 2019.
12. Khokhar AR, Iqbal T, Hussain M, Rehman QU. Seasonal variation in trachoma prevalence among children, District Dera Ghazi Khan of Punjab, Pakistan. *JPMA. The Journal of the Pakistan Medical Association*. 2021 Jan 1;71(1 (B)):201-4.
13. Burr SE, Sillah A, Sanou AS, Wadagni AC, Hart J, Harding-Esch EM, Kanyi S, Bailey RL. Cross-sectional surveys of the prevalence of follicular trachoma and trichiasis in The Gambia: has elimination been reached?. *PLoS neglected tropical diseases*. 2016 Sep 19;10(9):e0004906.
14. Shafi Abdurahman O, Last A, Macleod D, Habtamu E, Versteeg B, Dumessa G, Guye M, Nure R, Adugna D, Miecha H, Greenland K. Trachoma risk factors in Oromia Region, Ethiopia. *PLoS Neglected Tropical Diseases*. 2023 Nov 7;17(11):e0011679.
15. Renneker KK, Abdala M, Addy J, Al-Khatib T, Amer K, Badiane MD, Batcho W, Bella L, Bougouma C,

- Bucumi V, Chisenga T. Global progress toward the elimination of active trachoma: an analysis of 38 countries. *The Lancet Global Health*. 2022 Apr 1;10(4):e491-500.
16. Szwarcwald CL, Lopes MD, Borges de Souza Junior PR, Vaz Ferreira Gómez D, Luna EJ, da Silva de Almeida W, Damacena GN, Ribeiro Favacho JD, Germano de Frias P, Butcher R, Boyd S. Population prevalence of trachoma in nine rural non-indigenous evaluation units of Brazil. *Ophthalmic Epidemiology*. 2023 Nov 2;30(6):561-70.
17. Delelegn D, Tolcha A, Beyene H, Tsegaye B. Status of active trachoma infection among school children who live in villages of open field defecation: a comparative cross-sectional study. *BMC public health*. 2021 Dec;21:1-0.
18. Maciel AM, Ramos Jr AN, Gomes VD, Ferreira AF, Almeida NM, Gómez DV, Favacho JD, Maciel MM, Delerino AL, Pires Neto RD. Epidemiology and control of trachoma in the state of Ceará, Northeast Brazil, 2007-2021. *Revista da Sociedade Brasileira de Medicina Tropical*. 2023 Jan 23;56:e0207-2022.
19. WoldeKidan E, Daka D, Legesse D, Laelago T, Betebo B. Prevalence of active trachoma and associated factors among children aged 1 to 9 years in rural communities of Lemo district, southern Ethiopia: community based cross sectional study. *BMC infectious diseases*. 2019 Dec;19:1-8.
20. Chen X, Munoz B, Wolle MA, Woods G, Odonkor M, Naufal F, Mkocha H, West SK. Environmental factors and hygiene behaviors associated with facial cleanliness and trachoma in Kongwa, Tanzania. *PLoS neglected tropical diseases*. 2021 Oct 28;15(10):e0009902.

**Authors Contribution**

Concept and Design: Qaim Ali Khan  
Data Collection / Assembly: Muhammad Tahir, Nauroz Fatima  
Drafting: Qurat ul Ain Ghazanfar  
Statistical expertise: Benish Ali  
Critical Revision: Yasir Iqbal



# A Novel Approach – Extra-capsular Cataract Extraction under Topical Anesthesia

Muhammad Sharjeel<sup>1</sup>, Hafiza Sadia Imtiaz<sup>2</sup>, Muhammad Awais Ashraf<sup>3</sup>, Muhammad Rizwan Khan<sup>4</sup>, Irfan Ullah<sup>5</sup>

## Abstract:

**Objective:** To determine the efficacy of topical anesthesia for performing extra-capsular cataract extraction in patients with mature, hypermature and brunescant cataract.

**Methods:** Patients of either gender, between 40-80 years of age, with mature, hypermature and brunescant cataracts, having uneventful ECCE were included in this study at eye department of Gomal Medical College, from Jan 2022 to Dec 2022. Topical anesthesia was acquired by proparacaine hydrochloride 0.5% eye drops. Pain score from patient and satisfaction score from surgeon were assessed during each surgery and recorded on proforma. Data was analyzed using SPSS v 25.

**Results:** Out of 52 patients, 46.1% were male and 53.8% were female with mean age of  $60.7 \pm 6.5$  years. Mean pain score experienced by patients during surgery was  $2.86 \pm 1.32$  with the range of 1 to 7. Maximum patients (30.7%) experienced a score of 03 and none of the patients reported pain score above 07. Maximum pain was experienced at the time of suturing by majority of patients (53.84%). Surgeon's satisfaction score was also assessed and Mean satisfaction score found was  $8.24 \pm 2.39$  with the range of 03-10. Maximum score for surgeon's satisfaction was 10 in 3 cases (5.76%) and score of 8 was found in majority of patients (32.69%).

**Conclusion:** Thus, ECCE can be safely performed under topical anesthesia that helps in achieving tremendous patient's as well as surgeon's comfort during surgery. *Al-Shifa Journal of Ophthalmology 2024; 20(1): 33-39. © Al-Shifa Trust Eye Hospital, Rawalpindi, Pakistan.*

1. Gomal Medical College Dera Ismail Khan.
2. Mayo Hospital, Lahore
3. Multan Medical & Dental College Multan.
4. Faisalabad Medical University & Allied Hospital Faisalabad
5. Khyber Teaching Hospital Peshawar

Originally Received: 09 February 2024

Revised: 29 March 2024

Accepted: 5 April 2024

## Correspondence to:

Muhammad Sharjeel

Gomal Medical College Dera Ismail Khan

## Introduction:

Cataract is the cloudiness of normal crystalline lens that renders people unable to see clearly. It may cause blurred vision, reduced contrast, glare, haloes, and even diplopia that compels people to seek surgical advice. There are various approaches to cataract surgery that has evolved from intra-capsular cataract extraction to extra-capsular cataract extraction and phacoemulsification.<sup>1</sup>

Though phacoemulsification and its modifications has largely replaced the older techniques like ICCE (Intra Capsular Cataract Extraction), an ECCE (Extra Capsular Cataract Extraction) due to its potential benefits of small wound, less surgical time, use of ultrasonic vibrations to emulsify the lens, less or no sutures, and

early post-op recovery. But it has certain limitations where extra-capsular cataract extraction is still the method of choice as in hyper-mature cataract, brunescant cataract and in certain centers where phacoemulsification facilities are not available.<sup>2</sup>

For cataract surgery, the usual anesthesia techniques are general anesthesia, retrobulbar/peribulbar local anesthesia, sub-tenon local anesthesia, intra-cameral local anesthesia and topical use of drops or gels.<sup>3</sup> For many decades, retrobulbar/peribulbar with or without facial block remained the gold standard for performing cataract surgeries but the risk of blind needle injection has led to so many reported complications.<sup>4-13</sup> To lower the complications associated with needle blocks, the routine phacoemulsification procedures are now done under topical anesthesia by many ophthalmologists. Topical anesthesia is preferred because it provides sufficient patient comfort with lower incidence of complications compared to other types of anesthesia.<sup>14</sup> Though topical anesthesia is becoming the method of choice in phaco cases where sutureless and small incision makes it easy to perform but extra-capsular cataract extraction is still done under local anesthesia almost everywhere.

In our study, we have devised specific pattern of using topical anesthesia in the form of drops for extra-capsular cataract extraction to avoid the complications associated with peri-bulbar/retrobulbar. This study is unique in the sense of its specific pattern of using topical anesthesia drops and also because limited data is available for doing ECCE surgery under topical anesthesia.

### **Materials and Methods:**

After getting approval from ethical review committee, a written informed consent with demographic information was collected from each patient before participating in this study. Patients of either gender, between 40-80 years of age, with hyper

mature and brunescant cataracts under topical anesthesia were included in this study. Patients with early/immature cataract, mentally handicapped patients, patients with lower pain threshold, glaucoma and uveitis patients, patients with previous intra-ocular surgery were all excluded from this study. This prospective interventional quasi-experimental study included 52 patients (sample size was calculated using WHO formula and values taken from Junejo, et al., 2016 study) and it was conducted at eye department of Gomal Medical College, D.I. Khan from January 2022 to Dec 2022.

All patients underwent routine ophthalmic examination including uncorrected visual acuity (UVA), best corrected visual acuity (BCVA), Slit lamp biomicroscopy including cataract grading, Goldmann Applanation tonometry, and Fundus evaluation. Biometry of the respected eye was done to determine intra-ocular lens power. Patients were counselled regarding the surgical technique of extra-capsular cataract extraction and type of anesthesia used during the procedure.

After dilating the operating eye with Mydriacyl 1% eye drops, topical anesthesia was acquired by proparacaine hydrochloride 0.5% eye drops (Alcaine, Alcon Pharmaceuticals), 2 drops were instilled 3 minutes apart before starting the surgery. After using povidone iodine 5% solution and draping the eye, 3<sup>rd</sup> drop of topical anesthesia was instilled before giving partial thickness clear corneal incision from 10 O'clock to 2 O'clock position. After getting entry into anterior chamber with full thickness stab incision at 11 O'clock position, AC maintained with viscoelastic gel and capsulotomy done via cane opener technique. 4<sup>th</sup> drop of topical proparacaine was instilled either before converting partial thickness into full thickness corneal incision or just before the nucleus delivery. 5<sup>th</sup> and mostly the last drop was used just before suturing. After an irrigation and aspiration of cortical matter, rigid PMMA intraocular lens inserted and

corneal incision sutured with interrupted nylon 10/0 sutures. All surgeries were performed by a single ophthalmologist.

During the procedure, patients were asked about the level of pain from 0 to 10 based on numerical rating scale (NRS) and maximum pain was experienced at which step of surgery. Similar numerical scale from 0-10 was used to determine the surgeon's satisfaction level during surgery. All these information along with demographic details were recorded on specially designed proforma. If the patient had met any per-op complication that was also recorded.

Data was analyzed using SPSS v 25. Categorical variables were recorded as frequency and percentage while numerical data as Mean  $\pm$  SD and range.

### Results:

52 patients were included in our study. Out of which 24 (46.1%) were male and 28 were female (53.8%). Right eye was operated upon 32 cases (61.5%) and left eye in 20 cases (38.4%). Mean age noted was 60.7  $\pm$  6.5 years with range of 40-80 years.

Mean intraocular lens (IOL) power determined was 23  $\pm$  4.2 D with the range

of 18 -29 D. Mean Axial length (AL) recorded was 24  $\pm$  1.2 mm with the range of 17.6-27.3 mm. Mean pain score experienced by patients during surgery was 2.86 $\pm$ 1.32 with the range of 1 to 7. Maximum patients (30.7%) experienced a score of 03 and none of patients reported pain score above 07.

Patients were also asked for maximum pain felt at which step of surgery. Maximum pain was experienced at the time of suturing by majority of patients (53.84%) and among them who experienced pain during suturing, 71.42% have pain while taking scleral bite during suturing. 2 patients (3.84%) reported pain during all steps.

Surgeon's satisfaction score was also assessed for every patient during ECCE surgery. Mean satisfaction score was 8.24 $\pm$ 2.39 with the range of 03-10. Maximum score for surgeon's satisfaction was 10 in 3 cases (5.76%) and score of 8 was found in majority of patients (32.69%). Surgeon didn't encounter any major complication like positive vitreous pressure or excessive eye movements.

*Table 1: Demographic variables*

Groups	Total number of patients	Percentage
40-60 years	20	38.4%
61-80 years	32	61.5%

*Table 2: Types of cataract for ECCE*

Type of cataract	Frequency	Percentage
Mature cataract	07	13.4%
Hyper mature cataract	27	51.9%
Brunescent cataract	18	34.6%

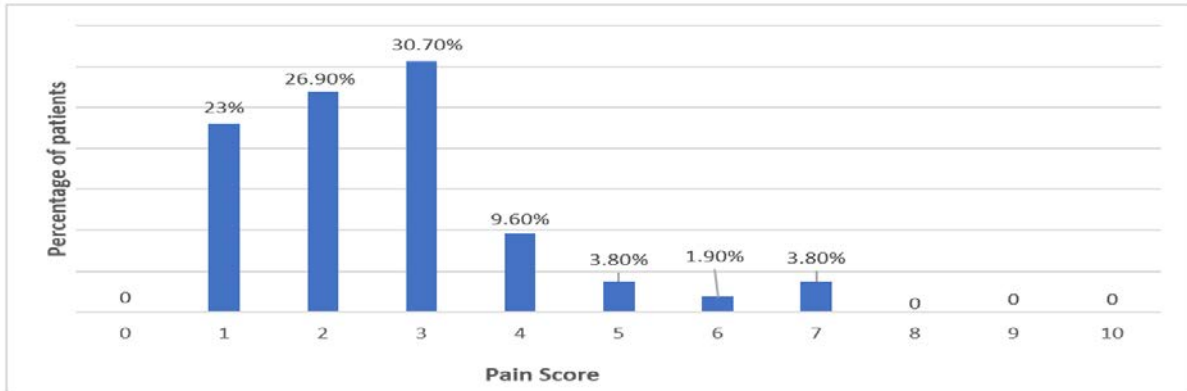


Fig 1: Column chart showing percentage of patients experiencing different pain scores

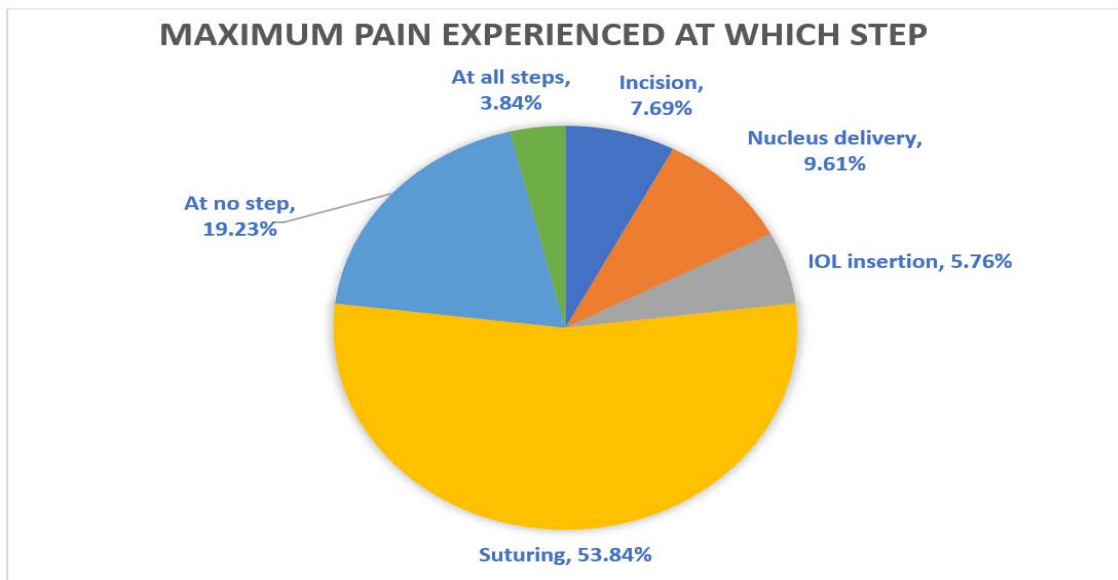


Fig. 2: Pie chart showing percentages of max. pain experienced at different steps

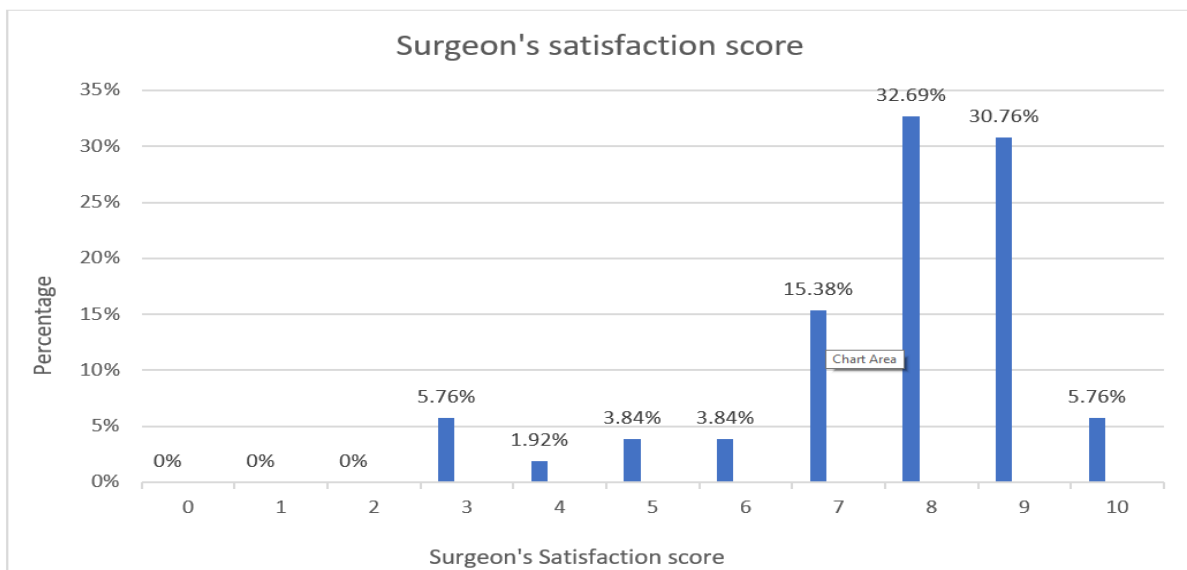


Fig.3: Column chart showing percentage of surgeon's satisfaction score during surgery 36

**Discussion:**

Cataract is most performed procedure when it comes to ophthalmic surgeries. During surgery, the surgeon as well as patient should be comfortable to have better post-op results while keeping the complications at minimum. Thus, the use of topical anesthesia allows the surgeons to eliminate the risks associated with needle injection and facilitate the patients who have needle phobia.

In our study, females were slightly more than males (53.8% versus 46.1%) and the mean age was 60.7 years. Higher female participation suggest that females tend to present later in the course of disease with mature cataracts and may be afraid of injections into the eyes. One similar study conducted in the same country reported mean age of 60.5 years with more male percentage than that of female.<sup>15</sup> This suggests that mean age of patients who come for cataract surgery remained almost same over the past decade.

Pain score was determined from every patient during surgery in our study. Mean pain score experienced by patients during surgery was  $2.86 \pm 1.32$  and maximum patients (30.7%) experienced a score of 03 and none of patients reported pain score above 07. Salahuddin conducted a similar study where phacoemulsification was done under topical anesthesia rather than ECCE and he reported mean pain score of 1.52 with range from 1-7, the results of which are comparable to our study.<sup>16</sup> Mean pain score from another similar study conducted in Turkey was 3.05 that was slightly higher than what reported in our population.<sup>17</sup> Patients were also enquired about maximum pain felt at which step and majority reported the maximum pain during suturing and that too while taking the scleral bite, the results are consistent with a similar study conducted by Abdul-Hamid.<sup>15</sup> In our study, we just determined the efficacy of topical anesthesia in ECCE without any comparison with peri-bulbar

block. Previously few researchers compared the topical versus peri-bulbar block in phacoemulsification cases and reported variable results.<sup>18,19</sup>

At one end, we determined the patient's perspective and on the other end we also kept in mind the surgeon's comfort that was determined in terms of surgeon's satisfaction score. Mean satisfaction score in our study was  $8.24 \pm 2.39$  with the range of 03-10. One study conducted in Jeddah for the use of topical anesthesia in phacoemulsification cases, reported that surgeon was very comfortable in 95% patients and in only 5% patients, mild discomfort was noted due to excessive movement of eyes that too controlled by vocally engaging the patients.<sup>20</sup>

So far, we have discussed the results of our study with those studies where topical anesthesia was used in phacoemulsification cases because very limited data is available for the use of topical anesthesia in extra-capsular cataract extraction cases. Thus, this study will help surgeons in building up the courage to carry out ECCE under topical anesthesia and thereby reducing the risk of complications associated with peri-bulbar or sub-tenon anesthesia.

The limitations of this study being single-centered, non-comparative, and having small sample size. Future endeavors will be done to target these limitations.

**Conclusion:**

In the light of above-mentioned results and discussion, we conclude that extra-capsular cataract extraction can be safely performed under topical anesthesia that helps in achieving tremendous patient's as well as surgeon's comfort during surgery.

**References:**

1. American Academy of Ophthalmology. Evaluation and Management of Cataracts. Basic and Clinical Science Course, Section 11. Lens and Cataract.

- San Francisco: American Academy of Ophthalmology; 2023-2024:79-93
2. Jaggernath J, Gogate P, Moodley V, Naidoo K. Comparison of Cataract Surgery Techniques: Safety, Efficacy, and Cost-Effectiveness. *European Journal of Ophthalmology*, 2014; 24 (4): 520-526.
  3. Shah R. Anesthesia for cataract surgery: Recent trends. *Oman J Ophthalmol* 2010; 3(3): 107-108. [PMID: 21120044]; [DOI: 10.4103/0974-620X.71881]
  4. Narendran S, Saravanan VR, Pereira M. Purtscher-like retinopathy: A rare complication of peribulbar anesthesia. *Indian J Ophthalmol* 2016; 64(6): 464-6. [PMID: 27488158]; [DOI: 10.4103/0301-4738.187679]
  5. Jung EH, Park KH, Woo SJ. Iatrogenic Central Retinal Artery Occlusion Following Retrobulbar Anesthesia for Intraocular Surgery. *Korean J Ophthalmol* 2015; 29(4): 233-40. [PMID: 26240507]; [DOI: 10.3341/kjo.2015.29.4.233]
  6. Lamichhane G, Gautam P. Central retinal arterial occlusion (CRAO) after phacoemulsification-a rare complication. *Nepal J Ophthalmol* 2013; 5(2): 281-3. [PMID: 24172572]; [DOI: 10.3126/nepjoph.v5i2.8746]
  7. Rodríguez Villa S, Salazar Méndez R, Cubillas Martín M, Cuesta García M. Central retinal artery occlusion after phacoemulsification under peribulbar anaesthesia: Pathogenic hypothesis. *Arch Soc Esp Oftalmol* 2016; 91(1): 40-3. [Article in English, Spanish] [PMID: 26652970]; [DOI: 10.1016/j.oftal.2015.10.003]
  8. Krilis M, Zeldovich A, Garrick R, Goldberg I. Vision loss and partial third nerve palsy following contralateral peribulbar anesthesia. *J Cataract Refract Surg* 2013; 39(1): 132-3. [PMID: 23245365]; [DOI: 10.1016/j.jcrs.2012.10.019]
  9. Gelaw Y, Abateneh A. Periocular necrotizing scleritis following retrobulbar injection. *Clin Ophthalmol* 2014; 8: 289-92. [PMID: 24511223]; [DOI: 10.2147/OPHTH.S58259]
  10. Kim CH, Kim US. Large exotropia after retrobulbar anesthesia. *Indian J Ophthalmol* 2016; 64(1): 91-2. [PMID: 26953032]; [DOI: 10.4103/0301-4738.178148]
  11. Blum RA, Lim LT, Weir CR. Diplopia following sub-tenon's anaesthesia: an unusual complication. *Int Ophthalmol* 2012; 32(2): 191-3. [PMID: 22350117]; [DOI: 10.1007/s10792-012-9535-3]
  12. Huebert I, Heinicke N, Kook D, Boost KA, Miller CV, Mayer WJ, Haritoglou C, Kampik A, Gandorfer A, Hintschich C, Wolf A. Dual platelet inhibition in cases of severe retrobulbar hemorrhage following retrobulbar and peribulbar anesthesia. *J Cataract Refract Surg* 2015; 41(10): 2092-101. [PMID: 26703284]; [DOI: 10.1016/j.jcrs.2015.10.051]
  13. Lee RM, Thompson JR, Eke T. Severe adverse events associated with local anaesthesia in cataract surgery: 1 year national survey of practice and complications in the UK. *Br J Ophthalmol* 2016; 100(6): 772-6. [PMID: 26405103]; [DOI: 10.1136/bjophthalmol-2015-307060]
  14. Fichman RA. Use of topical anesthesia alone in cataract surgery. *J Cataract Refract Surg* 1996; 22: 612-614. [PMID: 8784636]
  15. Awan AH. Subjective Assessment of Pain Level during Phacoemulsification and Extra Capsular Cataract Extraction with Intraocular Lens Implantation under Topical Anesthesia. *Pak J Ophthalmol*. 2009;25(3):161-4.
  16. Ahmed S. Cataract Surgery: Is it Time to Convert to Topical Anaesthesia? *Pak J Ophthalmol*. 2008;24(o):62-6.
  17. Apil A, Kartal B, Ekinci M, Cagatay HH, Keles S, Ceylan E, Cakici O.

- Topical anesthesia for cataract surgery: the patients' perspective. *Pain Res Treat* 2014; 2014: 827659. [PMID: 25050180]; [DOI: 10.1155/2014/827659]
18. Ahmad N, Zahoor A, Motowa SA, Jastaneiah S, Riad W. Satisfaction level with topical versus peribulbar anesthesia experienced by same patient for phacoemulsification. *Saudi J Anaesth* 2012; 6(4): 363-6. [PMID: 22365066]; [DOI: 10.1016/j.ophtha.2011.09.056]
19. Dole K, Kulkarni S, Shisode KD, Deshpande R, Kakade N, Khandekar R, Deshpande M. Comparison of clinical outcomes, patient, and surgeon satisfaction following topical versus peribulbar anesthesia for phacoemulsification and intraocular lens implantation: a randomized, controlled trial. *Indian J Ophthalmol* 2014 ; 62(9): 927-30. [PMID: 25370394.]; [DOI: 10.4103/0301-4738.143929]
20. Waheeb S. Topical anesthesia in phacoemulsification. *Oman J Ophthalmol.* 2010 Sep;3(3):136-9. doi: 10.4103/0974-620X.71892. PMID: 21120050; PMCID: PMC2992161.

**Authors Contribution**

Concept and Design: Hafiza Sadia Imtiaz  
Data Collection / Assembly: Muhammad Awais Ashraf  
Drafting: Muhammad Rizwan Khan  
Statistical expertise: Irfan Ullah  
Critical Revision: Muhammad Sharjeel

# Persistent High Intraocular Pressure (IOP) After Phaco Vitrectomy In A Case Of Trauma

Xianxin Gao<sup>1</sup>, Rong Zhao<sup>1</sup>, Guohua Wang<sup>1</sup>, Xiaonian Liu<sup>1</sup>

## Abstract:

This report delineates a case of persistent intraocular pressure (IOP) after trauma, phaco vitrectomy, necessitating repeated surgical interventions for effective management. A 51-year-old male presented with a history of right eye basketball injury, reporting a month-long experience of a dark shadow in his vision. Initial assessment revealed visual acuity (VA) of 50/100 in the right eye and 80/100 in the left eye, accompanied by elevated IOP (25 mmHg) and several ocular anomalies, including lens opacity and vitreous hemorrhage. Surgical procedures, including phacoemulsification, intraocular lens (IOL) implantation, vitrectomy, gas-liquid exchange, and retinal laser photocoagulation, were performed on the right eye. Despite these interventions, persistent high IOP necessitated further management, including anterior chamber punctures followed by tube implant. *Al-Shifa Journal of Ophthalmology* 2024; 20(1): 40-43. © Al-Shifa Trust Eye Hospital, Rawalpindi, Pakistan.

1. Yichang Aier Eye Hospital of Aier Eye Hospital, Yichang 443000, Hubei Province, China.

Originally Received: 12 Sep 2022

Revised: 29 Sep 2023

Accepted: 5 April 2024

## Correspondence to:

Xianxin Gao

Yichang Aier Eye Hospital of Aier Eye Hospital, Yichang 443000, Hubei Province, China.

gaoxianxin@163.com

## Introduction:

Traumatic glaucoma are a group of secondary glaucoma that occur because of various mechanisms occurring after injury to the eye. In addition to glaucoma, trauma may also result in various anterior and posterior segment complications. Pars plana vitrectomy (PPV) is a widely employed surgical procedure for the treatment of posterior segment ocular diseases. However, postoperative elevation of IOP is a frequently encountered complication, with reported incidences ranging from 8.4% to 83.3%. This complication, if left unaddressed or poorly managed, can lead to irreversible visual impairment. Herein, we present a case of high IOP following blunt ocular trauma, vitrectomy, and concomitant cataract surgery, necessitating multifaceted management strategies.

## Case Presentation:

A 51-year-old male presented to the Comprehensive Eye Department one month after sustaining a basketball-related eye injury. He reported transient visual impairment followed by progressive eye



swelling, prompting medical attention. Upon examination, elevated IOP in the right eye, along with various ocular abnormalities including cataract and vitreous hemorrhage was noted. However, the retina was found flat. After initial medical management for the raised IOP and intraocular inflammation, surgical intervention (phacoemulsification, IOL implantation, vitrectomy, and retinal laser photocoagulation) was performed. Although post operatively visual acuity of

the right eye improved, the patient continued to experience persistent elevation of IOP. Subsequent management involved systemic anti-inflammatory therapy, local infection prevention, and multiple anterior chamber punctures aimed at mitigating elevated IOP.

Despite of these interventions, the IOP still remained high and the patient was advised to undergo glaucoma drainage device implant.

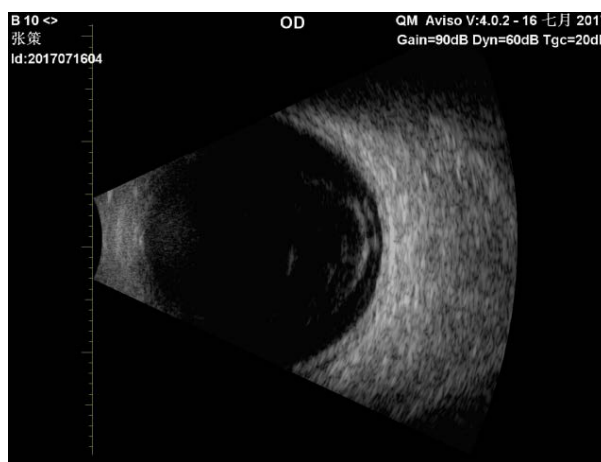
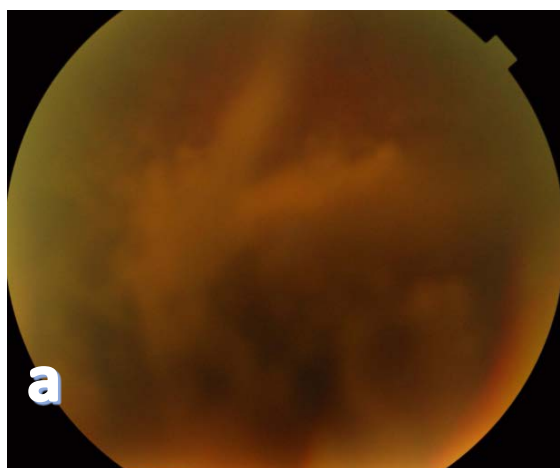


Fig.1 Right eye vitreous hemorrhage. Fundus photography reveals that the fundus view is not clear due to vitreous hemorrhage.

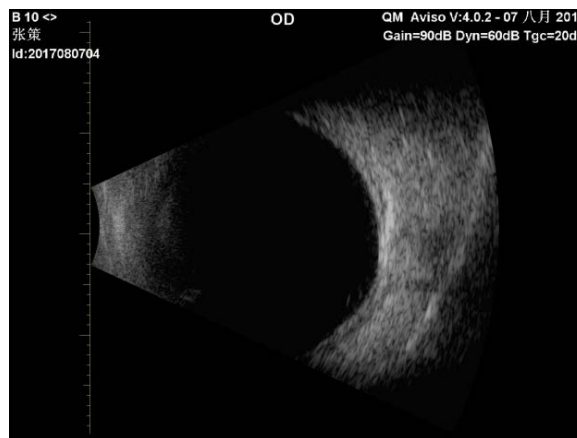
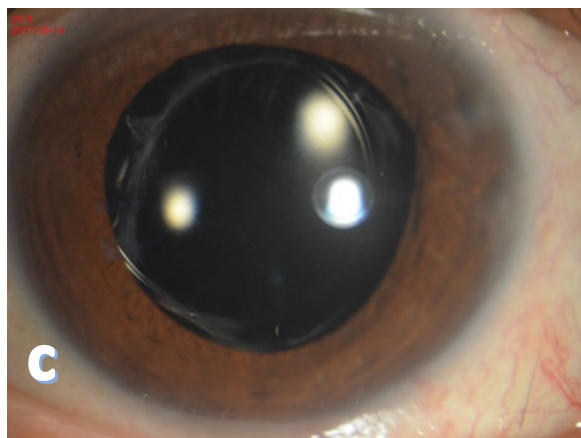


Fig.2 Anterior segment of the right eye after surgery and IOL implant. B ultrasound of the right eye indicates that the vitreous blood is cleared.

**Discussion:**

Analysis of this case reveals several potential mechanisms underlying elevated IOP after blunt ocular trauma and vitrectomy. These encompass damage to the trabecular meshwork, inflammation-

induced debris blockage, intraocular hemorrhage, alterations in lens morphology and position, vitreous herniation, Schwaltz syndrome and angle recession<sup>1,2,3</sup>. Treatment modalities for elevated IOP following trauma are diverse, each bearing

its unique advantages and drawbacks. While PPV has revolutionized the management of posterior segment ocular pathologies, it also poses the risk of postoperative complications such as elevated IOP.<sup>4</sup>

A thorough comprehension of the underlying pathophysiological mechanisms and associated risk factors is essential for developing efficient management and preventive strategies. Instances of such cases pose a surgical challenge due to conjunctival scarring resulting from previous retinal surgeries, rendering standard filtering surgeries technically demanding and less likely to succeed, even with the additional use of antimetabolites.<sup>5,6</sup> Trabeculectomy with mitomycin C is a commonly performed procedure for glaucoma, but its success hinges on the survival of the bleb, while conjunctival scarring post-ocular surgery stands as a significant risk factor for surgical failure. When conservative measures prove insufficient in controlling intraocular pressure (IOP), the placement of a tube implant, like the Ahmed glaucoma drainage valve, may be considered as a permanent solution. This surgical intervention provides a dependable method of facilitating drainage of aqueous humor, effectively reducing IOP and minimizing the risk of optic nerve damage and irreversible vision loss. Therefore, the possibility of tube implantation should be contemplated in cases of stubbornly high IOP following phacoemulsification combined with vitrectomy.<sup>7,8</sup>

### **Conclusion:**

This case underscores the challenge of managing elevated IOP following blunt ocular trauma and vitrectomy. Comprehensive understanding of the underlying etiology is paramount for informed clinical decision-making and effective treatment strategies. Despite exhaustive efforts, conservative measures such as anterior chamber punctures failed to

achieve sustained IOP control in our patient. In such cases, where medical management proves inadequate, surgical intervention in the form of a tube implant may be warranted as a permanent solution. Tube implants, such as the Ahmed glaucoma drainage valve, offer a reliable means of facilitating aqueous humor drainage, thereby effectively lowering IOP and mitigating the risk of optic nerve damage and irreversible vision loss.

### **References:**

1. Li J, Liu SM, Dong WT, et al. Outcomes of transconjunctival sutureless 27-gauge vitrectomy for vitreoretinal diseases. *Int J Ophthalmol.* 2018;11:408-415. PMID: 29600174 DOI: 10.18240/ijo.2018.03.10
2. Hee Kyung Y, Yang S, Joon W, Kyu Hyung P, Ki Ho P. Intraocular pressure changes after vitrectomy with and without combined phacoemulsification and intraocular lens implantation. *Korean J Ophthalmol.* 2010;24:341-6. PMID: 21165232 DOI: 10.3341/kjo.2010.24.6.341
3. Girkin CA, McGwin G Jr, Long C, et al. Glaucoma after ocular contusion: a cohort study of the United States Eye Injury Registry. *J Glaucoma.* 2005;14:470-473. PMID: 16276279 DOI: 10.1097/01.ijg.0000185437.92803.d7
4. Kovacic H, Wolfs RCW, Kılıç E, et al. The effect of multiple vitrectomies and its indications on intraocular pressure. *BMC Ophthalmol.* 2019;19:175. PMID: 31395046 DOI: 10.1186/s12886-019-1187-x
5. Ivastinovic D, Smiddy WE, Wackernagel W, et al. The occurrence of delayed ocular hypertension and glaucoma after pars plana vitrectomy for rhegmatogenous retinal detachment. *Acta Ophthalmol.* 2016;94:e525-e527. PMID: 26805488 DOI: 10.1111/aos.12925
6. Broadway DC, Chang LP. Trabeculectomy, risk factors for failure

- and the preoperative state of the conjunctiva. *J Glaucoma*. 2001; 10: 237–249.
7. Yamamoto K, Iwase T, Terasaki H. Long-term changes in intraocular pressure after vitrectomy for rhegmatogenous retinal detachment, epi-retinal membrane, or macular hole. *PLoS One*. 2016;11:e167303. PMID: 27898707 DOI: 10.1371/journal.pone.0167303
8. Adel M, Al-Jazzaf, Peter A, Netland, Steve, Charles. Incidence and management of elevated intraocular pressure after silicone oil injection. *J Glaucoma*. 2005;14:40-6. PMID: 15650603 DOI: 10.1097/01.ijg.0000145811.62095.fa

**Authors Contribution**

Concept and Design: Rong Zhao  
Data Collection / Assembly: Guohua Wang  
Drafting: Xiaonian Liu  
Statistical expertise: Rong Zhao  
Critical Revision: Xianxin Gao