



ASJO

ISSN 3006-2543 (Online)

ISSN 1990-3863 (Print)

AL-SHIFA JOURNAL OF OPHTHALMOLOGY

An Open Access, Peer Reviewed, Quarterly Journal of
AL-SHIFA TRUST EYE HOSPITAL

Vol. 19, No. 4, October - December 2023

Indexed in

WHO Index Medicus (IMEMR)

Asian Digital Library (ADL)

Pak Medinet

Pakistan Medical and Dental Council IP/033

ISSN 3006-2543 (Online)
ISSN 1990-3863 (Print)

**A
S
J
O**

Al-Shifa Journal of Ophthalmology

Vol. 19, No. 4, October - December 2023 (Index Issue)

QUARTERLY PUBLISHED

- **Editorial: Avastin Injection: Shedding Light on Ethical Dilemma**
- **Navigating Pediatric Ophthalmological Disorders**
- **Corneal Donations Knowledge Among Medical Students**
- **Ranibizumab vs. Bevacizumab in Diabetic Macular Edema**
- **Practice Trends of Optometrists and Refractionists Regarding Myopia**
- **Causative Bacteria in Acute vs Chronic Dacryocystitis**

Abstracts available at <https://www.asjoalshifaeye.org> and <http://www.pakmedinet.com/ASJO>
Manuscript submission through online platform ejmanager.com

Indexed in Index Medicus -EMR

Recognized by Pakistan Medical & Dental Council – IP/033

Al-Shifa Journal of Ophthalmology

Editorial inquiries should be addressed to Prof. Dr. Tayyab Afghani, Department of Orbit and Oculoplastics, Al-Shifa Trust Eye Hospital, Jhelum Road Rawalpindi, Pakistan.
Tel: 0092 51 5487821-25, Fax: 0092 51 5487827; Email: aqrcpio@yahoo.com ;
Website: www.asjoalshifaeye.org

Editorial: Shedding Light on the Ethical Dilemma: The Avastin Injection Crisis in Punjab Mahmood Ali	137
Clearing the Path to Healthy Vision: Navigating Common Pediatric Ophthalmological Disorders Sidrah Riaz, Muhammad Tariq Khan, Samina Bilal, Hussain Ahmad Khaqan, Muhammad Saghir	139
Attitudes and Knowledge of Corneal Donation among Medical Students of Poonch Medical College, Rawalakot Muqet Ahmed Zaheer, Hira Naveed, Ali Amjad, Safa Tariq, Muhammad Muneebullah Siddiqui, Azhar Iqbal	145
To Compare the mean Difference in Central Macular Thickness and Best Corrected Visual Acuity in Patients of Diabetic Macular Edema Receiving Intravitreal Ranibizumab versus Bevacizumab Rehan Saleem , Afia Matloob rana, Waseem Akhter , Salman Tariq Toosy, Fuad Khan Niazi, Irum Yousafzai	154
Knowledge and Practice trends of Optometrists and Refractionists at LRBT Regarding Myopia Muhammad Nadeem, Adnan Afsar	162
Comparison Of Causative Bacteria In Acute And Chronic Dacryocystitis Sara Najeeb, Muhammad Usman Sadiq, Umair Tariq Mirza, Fatima Akbar Shah, Muhammad Irfan Sadiq, Muhammad Shuaib	172
Author Index	178
Subject Index	186

To Compare the Mean Difference in Central Macular Thickness and Best Corrected Visual Acuity in Patients of Diabetic Macular Edema Receiving Intravitreal Ranibizumab versus Bevacizumab

Rehan Saleem¹, Afia Matloob Rana², Waseem Akhter³, Salman Tariq Toosy⁴, Fuad Khan Niazi⁵, Irum Yousafzai³

Abstract:

Objectives: To compare the efficacy of two anti VEGF ranibizumab and bevacizumab in diabetic macular edema.

Methods: It was a randomized control trial conducted at Eye department of Holy Family Hospital Rawalpindi 23rd April 2021 to 23rd April 2022. A total 60 patients (30 in each group) with diabetic macular edema of age range from 15-65 years. In Group A 30 patients received three consecutive monthly intravitreal injection of ranibizumab 0.03mg/0.05ml. In Group B 30 patients received three consecutive monthly intravitreal injection of bevacizumab 1.25mg/0.05ml. After 3 months best corrected visual acuity and central macular thickness was recorded. Data was entered and analyzed by using SPSS VERSION 22.

Results: Total 60 patients were included in the study, 30 in each group. The mean age of patients in group A was 38.67 ± 7.88 years and in group B was 39.43 ± 8.02 years. Out of 60 patients, 45 (75.0%) were female and 15 (25.0%) were male. The reduction in central macular thickness (CMT) after three months with intravitreal bevacizumab and ranibizumab was 342.23 ± 6.41 and 320.10 ± 9.79 respectively (p-value = 0.0001). The improvement in best corrected visual acuity with intravitreal bevacizumab and ranibizumab after three month was 0.45 ± 0.02 and 0.48 ± 0.03 (p-value = 0.0001).

Conclusion: This study concluded that ranibizumab is better as compared to bevacizumab in terms of mean central macular thickness and best corrected visual acuity in patients of diabetic macular edema. *Al-Shifa Journal of Ophthalmology 2023; 19(4): 154-161.* © Al-Shifa Trust Eye Hospital, Rawalpindi, Pakistan.

1. Shifa College of Medicine, Islamabad.
2. HBS Medical and Dental College, Islamabad.
3. Rawal Institute of Health Sciences, Islamabad.
4. DHQ, Rawalpindi Teaching Hospital.
5. RMC and Allied Hospitals, Rawalpindi.

Originally Received: 19 August 2023

Revised: 21 August 2023

Accepted: 6 September 2023

Correspondence to:

Afia Matloob Rana

Email: afiamatloob@yahoo.com

Introduction:

Diabetes is multiorgan, metabolic disease of public health concern worldwide¹. According to the International Diabetes Federation in 2022, 26.7% of adults in Pakistan are affected by diabetes making the total number of cases approximately 33million¹. Diabetic retinopathy is major cause of visual impairment in working age adults worldwide². Diabetic retinopathy is a microangiopathy in which small blood vessels are particularly vulnerable to damage from hyperglycaemia. The pathogenic factors involved in diabetic retinopathy are cellular damage due to

intracellular sorbitol accumulation, oxidative stress due to free radical excess, accumulation of advanced glycation end products (AGE) and excess activation of several protein kinase C isoforms³. Vascular endothelial growth factor causes angiogenesis and increase in retinal vascular permeability by increasing the phosphorylation of the tight junction proteins.

Diabetic macular edema is major cause of visual impairment in diabetics and its pathogenesis is multifactorial and still not completely understood. Alteration of blood retinal barrier is the hallmark of diabetic macular edema which can lead to death of pericytes, thickening of capillary basement membrane, loss of smooth muscles, and proliferation of endothelial cells. Macular edema divides into Focal diabetic macular edema which is caused by accumulation of fluid from leaking microaneurysms and diffuse macular edema which is caused by leakage without any clear source. The fluid initially located between outer plexiform and inner nuclear layer latter it may involve the inner plexiform and nerve fibre layer until the entire thickness of retina become edematous⁴. Based on OCT, cystoid macular edema is considered as intraretinal cystoid-like, hypo-reflective spaces with highly reflective septa separating the cystoid-like spaces⁵.

Available treatment options for diabetic macular edema are laser photocoagulation, intravitreal corticosteroids and intravitreal anti-VEGF. Conventional Laser treatment reduces the risk of moderate visual loss by approximately 50% without guaranteeing remarkable effects on visual improvement. Laser photocoagulation is standard treatment previously but now intravitreal anti-vascular endothelial growth factors (anti-VEGF) is considered first line because of better anatomical and functional outcome⁶. Along with anti-VEGF treatment rigorous diabetic control plays very important role.⁶

Now anti-VEGF is considered as first line treatment for diabetic macular edema.

Currently different anti-VEGF agents are available in market with different clinical effects and pharmacological properties. Three anti-VEGF agents are mainly used in clinical practice to improve vision loss associated with DME: Aflibercept (Eylea®), Ranibizumab (Lucentis) and Bevacizumab (Avastin®)⁷.

In our study we compared effect of intravitreal ranibizumab and bevacizumab on diabetic macular edema. Bevacizumab is complete humanized monoclonal antibody and much cheaper. The dose of bevacizumab is 2.5mg/0.1ml. It was mainly used for cancer therapy and its ocular use is off-label and is not commercially available for ocular use.⁸.

Ranibizumab anti-VEGF is a monoclonal antibody fragment. It selectively binds to inhibit all isoforms of VEGF A. The usual dose is 0.5mg in 0.05ml. Ranibizumab is as cost effective as laser in the treatment of diabetic macular edema. Side effects associated with anti-VEGF are increase in blood pressure, MI, transient ischemic attack, stroke, thromboembolic event⁹. The FDA approved ranibizumab (Lucentis) for diabetic macular edema in August 2012⁹.

In real world study conducted by Olufemi O et al, the BCVA for eyes that received Bevacizumab at baseline, 4 months, 6 months and 9 months post injection were 0.32 ± 0.16 , 0.32 ± 0.17 , 0.40 ± 0.24 0.44 ± 0.26 respectively while in eyes that received Ranibizumab, the mean BCVA at baseline, 4 months, 6 months and 9 months post injection was 0.33 ± 0.29 , 0.40 ± 0.26 , 0.43 ± 0.26 , 0.41 ± 0.26 respectively¹⁰.

The purpose of our study is to compare the efficacy of two anti VEGF ranibizumab and bevacizumab in diabetic macular edema, which anti-VEGF causes more decrease in central macular thickness and gives better best corrected visual acuity.

Materials and Methods:

It was a randomized control trial conducted at Eye department of Holy Family Hospital Rawalpindi for duration of one year from 23rd April 2021 to 23rd April 2022. Total 60

patients (30 in each group) with diabetic macular edema of age range from 15-65 years of both genders and both type I and type II diabetes were selected. Patients with previous history of PRP, Vitreoretinal surgery, intravitreal steroids, tractional retinal detachment, Epiretinal membrane and those with H/O Cerebral vascular accidents or MI within 3 months prior to anti- VEGF were excluded from the study. After approval letter from Institutional Research Forum of RMU, patient fulfilling selection criteria were included in the study after Informed consent. After explaining them procedure of study, patients were allocated study groups as mentioned in sampling technique. In patient having diabetic macular edema, Baseline Best Corrected Visual acuity and Central Macular Thickness by optical coherence tomography was recorded prior to any intravitreal injection. Patients were divided into two groups based on their choice of anti-VEGF. Injections were given either ranibizumab or bevacizumab to the patients keeping in view their affordability. Group A, 30 patients received three consecutive monthly intravitreal injection of ranibizumab 0.03mg/0.05ml. Group B, 30 patients received three consecutive monthly intravitreal injection of bevacizumab 1.25mg/0.05ml. All intravitreal injection were given 4mm posterior to the limbus if eye is aphakic or 3mm posterior to the limbus if eye is pseudophakic through pars plana with 30-gauge needles under topical anaesthesia. All patients were followed up on monthly basis. After 3 months best corrected visual acuity and central macular thickness was recorded. All the information was recorded in the structured pre designed Performa of the study. Data was entered and analyzed by using SPSS VERSION 22. Mean and standard deviation was calculated for all quantitative variables like age, duration of Diabetes, macular thickness and best corrected visual acuity. Frequency and percentages% were calculated for qualitative variable like gender and control of Diabetes.

Independent sample T- test at 5% level of significance was used to compare means of macular thickness and best corrected visual acuity in both study groups. Independent sample T-test at 5% level of significance was also used to compare changes in means of macular thickness and best corrected visual acuity in both groups. Effect modifier like duration, control of Diabetes, age and gender were controlled by stratifications. Post stratification independent sample t-test was applied. P Value less than 0.05% was taken as a significant.

Results:

Total 60 patients (30 in each group) with diabetic macular edema of age range 15-65 years of both genders and both types of diabetes were included in the study. Age range in this study was from 15 to 65 years with mean age of 39.05 ± 7.90 years. The mean age of patients in group A was 38.67 ± 7.88 years and in group B was 39.43 ± 8.02 years. Majority of the patients 47 (78.33%) were between 25 to 45 years of age as shown in Table 1.

Out of these 60 patients, 45 (75.0%) were female and 15 (25.0%) were males with male to female ratio of ratio of 1:3 (Figure IV). Mean duration of DM was 6.23 ± 2.46 years (Table 2). Distribution of patients according to control of DM is shown in Table 3.

In this study, the reduction in central macular thickness with intravitreal bevacizumab and ranibizumab after three months was 342.23 ± 6.41 and 320.10 ± 9.79 respectively (p-value = 0.0001). The improvement in best corrected visual acuity with intravitreal bevacizumab and ranibizumab after three month was 0.45 ± 0.02 and 0.48 ± 0.03 (p-value = 0.0001) as shown in Table 4. Stratification of Best Corrected Visual Acuity with respect to age, gender, duration of disease and control of DM is shown in Table 5. Stratification of central macular thickness with respect to age, gender, duration of disease and control of DM is shown in Table 6.

Table 1: Age distribution for both groups (n=60)

Age (years)	Group A (n=30)		Group B (n=30)		Total (n=60)	
	No. of patients	% age	No. of patients	% age	No. of patients	% age
15-45	24	80.0	23	76.67	47	78.33
46-65	06	20.0	07	23.33	13	21.67
Mean ± SD	38.67 ± 7.88		39.43 ± 8.02		39.05 ± 7.90	

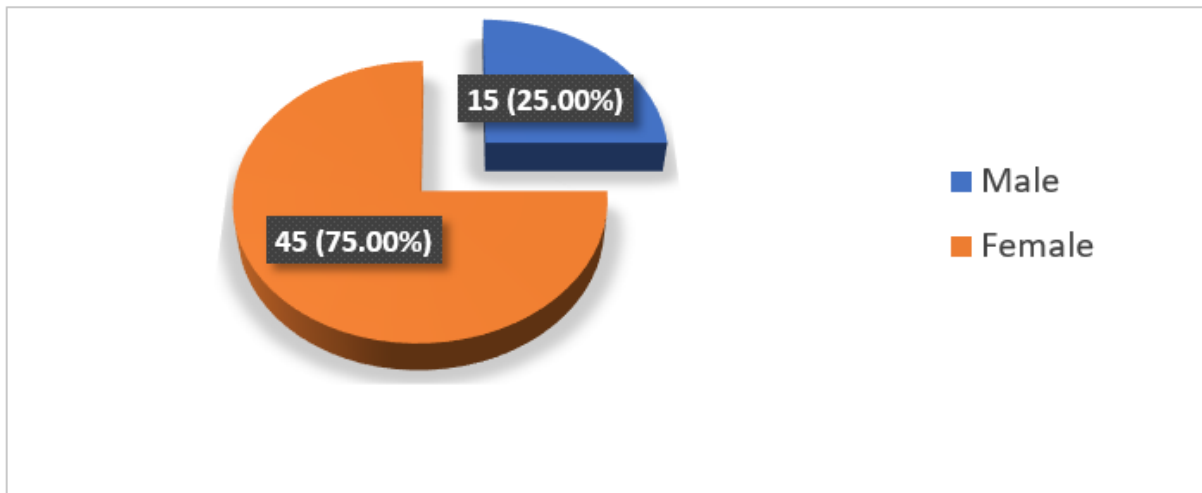


Figure 1: Distribution of patients according to Gender (n=60)

Table 2: Distribution of patients according to duration of DM.

Duration (yrs)	Group A (n=30)		Group B (n=30)		Total (n=60)	
	No. of patients	% age	No. of patients	% age	No. of patients	% age
≤5	15	50.0	14	46.67	29	48.33
>5	15	50.0	16	53.33	31	51.67
Mean ± SD	6.23 ± 2.46		6.23 ± 2.44		6.23 ± 2.46	

Table 3: Distribution of patients according to control of DM.

Control	Group A (n=30)		Group B (n=30)		Total (n=60)	
	No. of patients	% age	No. of patients	% age	No. of patients	% age
Yes	10	33.33	10	33.33	20	33.33
No	20	66.67	20	66.67	40	66.67

Table 4: Comparison the mean difference in Central Macular Thickness and Best Corrected Visual Acuity in patients of diabetic macular edema receiving Ranibizumab versus those receiving Bevacizumab.

Outcome	Group A (n=30)	Group B (n=30)	p-value
	Mean ± SD	Mean ± SD	
Best Corrected Visual Acuity	0.48 ± 0.03	0.45 ± 0.02	0.0001
Central Macular Thickness	320.10 ± 9.79	342.23 ± 6.41	0.0001

Table 5: Stratification of Best Corrected Visual Acuity with respect to age, gender, duration of disease and control of DM.

Co-morbid conditions		Group A (n=30)		Group B (n=30)		P-value
		Best Corrected Visual Acuity		Best Corrected Visual Acuity		
		Mean	SD	Mean	SD	
Age (years)	15-45	0.49	0.03	0.45	0.02	0.0001
	46-65	0.48	0.02	0.45	0.02	0.0001
Gender	Male	0.49	0.03	0.45	0.02	0.0001
	Female	0.48	0.03	0.45	0.02	0.0001
Duration (months)	≤5	0.49	0.03	0.45	0.02	0.0001
	>5	0.48	0.02	0.45	0.02	0.0001
Controlled	Yes	0.48	0.03	0.45	0.02	0.0001
	No	0.49	0.03	0.46	0.02	0.0001

Table 6: Stratification of Central Macular Thickness with respect to age, gender, duration of disease and control of DM.

Co-morbid conditions		Group A (n=30)		Group B (n=30)		P-value
		Central Macular Thickness		Central Macular Thickness		
		Mean	SD	Mean	SD	
Age (years)	15-45	319.25	10.12	342.48	6.44	0.0001
	46-65	323.50	8.17	341.43	6.73	0.0001
Gender	Male	316.0	5.90	342.14	5.76	0.0001
	Female	321.59	10.58	342.26	6.72	0.0001
Duration (months)	≤5	318.27	9.75	343.0	7.01	0.0001
	>5	321.93	9.80	341.56	5.99	0.0001
Controlled	Yes	316.70	9.36	343.0	5.71	0.0001
	No	321.80	9.77	341.85	6.84	0.0001

Discussion:

Diabetes is a major global health burden in working age group due to its complications. Diabetic retinopathy is one of the major complications of uncontrolled diabetes and occurs in 30-40% of diabetics¹¹.

In 2020, the number of adults worldwide with Diabetic Retinopathy, Vision Threatening DR, and Macular Edema was estimated to be 103.12 million, 28.54 million, and 18.83 million, respectively; and the numbers are projected to increase up to 160.50 million, 44.82 million, and 28.61

million, respectively by 2045¹².

There has been continuous increase in prevalence of diabetes in Pakistan. The National Diabetes Survey of Pakistan (NDSP 2016–2017) had reported that the prevalence of diabetes was 26.3% in Pakistan¹³. The study conducted by Jokhio AH et al diabetes prevalence is very high in rural population of Pakistan. Prevalence of clinically established DR, was 24.2% (95% CI, 22–26%). Age group >60 years and females had significantly more DR 40.5% and 58.1% respectively¹⁴.

Diabetic macular edema is leading cause of visual loss and meta- analysis yield its global prevalence of 5.47% among diabetics and it is increasing with each passing year¹⁵.

Antivascular endothelial growth factors are first line treatment in management of diabetic macular edema. In study conducted by Lundeen EA et al the 10 years trend of management of DME indicates use of Anti-vascular endothelial growth factor injections annual prevalence doubled among those with DME 15.7% to 35.2%¹⁶.

Anti-VEGF is effective treatment modality and results in anatomical as well as functional improvement. Bevacizumab is most commonly used anti-VEGF due to its cost effectiveness and Intravitreal bevacizumab resulted in decrease in central macular thickness and improvement in BCVA in case of DME in study conducted by Sharma S et al¹⁷.

Ranibizumab is effective, safe and FDA proved anti-VEGF. Global LUMINOUS study showed improvement in baseline VA after intravitreal ranibizumab for DME. At 1-year, mean VA letter score improved by +3.5 (n = 502) from a baseline of 57.7 with a mean of 4.5 injections. Rather than RCT this study indicates safety and efficacy of ranibizumab in real world clinical practices¹⁸.

Previously multicenter RISE, RIDE and

RESTORE clinical trials evaluate efficacy of IV ranibizumab and showed improvement in BCVA and Macular thickness with IV ranibizumab¹⁹.

Olufemi O et al reported that 36 eyes with diabetic macular edema were enrolled in their study and at 4 months a larger percentage of eyes (47.6%) that received Ranibizumab had better visual acuities compared to (13.3%) eyes that received Bevacizumab. At 6 months, (26.7%) of eyes that received Ranibizumab had better visual acuities compared to 23.8% that received Bevacizumab. At 9 months, (33.3%) of eyes that received Ranibizumab had better visual acuities compared to (19%) of those that received Bevacizumab. This difference between two anti-VEGF was not statistically significant²⁰.

Our results are also supported by another study conducted by Malik HA in Pakistan in which there is statistically significant improvement in visual acuity was observed in both the groups of intravitreal bevacizumab and ranibizumab for diabetic macular edema. There was also improvement in central retinal thickness and macular volume in both the groups but difference was not statistically significant²¹.

In another study of twenty-three eyes of nineteen patients conducted by Mirshahi R et al showed improvement in central macular subfield thickness from $418.30 \pm 103.06 \mu\text{m}$ to $404.91 \pm 115.48 \mu\text{m}$ before and 1 month after IV bevacizumab²². However, in contrast to this, there is another observational retrospective study carried out on bevacizumab resistant macular odema. Mean Central Macular Thickness decreased from $444.9 \pm 109.2 \mu\text{m}$ to $316.3 \pm 54.5 \mu\text{m}$ after ranibizumab in these patients. Also, the mean BVCA increased from 49.9 ± 12.0 ETDRS letters to 61.1 ± 9.1 . Treatment with intravitreal ranibizumab contribute to better visual and anatomical outcomes²³. Our study has many shortcomings in

terms of small sample size, single center and no long term follow up of patient. There are also many other factors that play important role in improvement of diabetic macular edema like diabetic nephropathy. However, our study results should be useful for clinicians who wants to use FDA approved anti-VEGF. We recommend this study with multicenter approach, comparison with other anti-VEGF agents with frequency of intravitreal injections should be explored with large sample size.

Conclusion:

This study concluded that the ranibizumab is better as compared to bevacizumab in terms of mean central macular thickness and best corrected visual acuity in patients of diabetic macular edema. So, we recommend that intravitreal ranibizumab should be used in diabetic macular edema patients for preventing advance visual functional defects.

References:

1. Azeem S, Khan U, Liaquat A. The increasing rate of diabetes in Pakistan: A silent killer. *Annals of Medicine and Surgery*. 2022 Jul;79.
2. Purola PK, Ojamo MU, Gissler M, Uusitalo HM. Changes in visual impairment due to diabetic retinopathy during 1980–2019 based on nationwide register data. *Diabetes Care*. 2022 Sep 1;45(9):2020-7.
3. Ansari P, Tabasumma N, Snigdha NN, Siam NH, Panduru RV, Azam S, Hannan JM, Abdel-Wahab YH. Diabetic retinopathy: an overview on mechanisms, pathophysiology and pharmacotherapy. *Diabetology*. 2022 Feb 15;3(1):159-75.
4. Santos AR, Santos T, Alves D, Marques IP, Lobo C, Cunha-Vaz J. Characterization of initial stages of diabetic macular edema. *Ophthalmic Research*. 2019 Nov 21;62(4):203-10.
5. Zhang J, Zhang J, Zhang C, Zhang J, Gu L, Luo D, Qiu Q. Diabetic macular edema: current understanding, molecular mechanisms and therapeutic implications. *Cells*. 2022 Oct 25;11(21):3362.
6. Zas M, Cotic M, Wu M, Wu A, Wu L. Macular laser photocoagulation in the management of diabetic macular edema: Still relevant in 2020?. *Taiwan Journal of Ophthalmology*. 2020 Apr;10(2):87.
7. Figueira J, Henriques J, Carneiro Â, Marques-Neves C, Flores R, Castro-Sousa JP, Meireles A, Gomes N, Nascimento J, Amaro M, Silva R. Guidelines for the management of center-involving diabetic macular edema: treatment options and patient monitorization. *Clinical Ophthalmology*. 2021 Jul 30:3221-30.
8. Falcão M. Impact of intravitreal ranibizumab therapy on vision outcomes in diabetic macular edema patients: a meta-analysis. *Kompass Ophthalmologie*. 2020 Oct 1;6(Suppl. 1):2-10.
9. Arrigo A, Aragona E, Bandello F. VEGF-targeting drugs for the treatment of retinal neovascularization in diabetic retinopathy. *Annals of Medicine*. 2022 Dec 31;54(1):1089-111.
10. Olufemi O, Adekunle H, Idris O. A Comparison of Visual Outcomes Between Patients Treated with Intravitreal Ranibizumab and Bevacizumab for Diabetic Macula Edema in A Real World Setting in Sub-Saharan Africa. *Ophthalmol Res*. 2022;5(1):1-5.
11. Tan TE, Wong TY. Diabetic retinopathy: Looking forward to 2030. *Frontiers in Endocrinology*. 2023 Jan 9;13:1077669.
12. Teo ZL, Tham YC, Yu M, Chee ML, Rim TH, Cheung N, Bikbov MM, Wang YX, Tang Y, Lu Y, Wong IY. Global prevalence of diabetic retinopathy and projection of burden through 2045: systematic review and meta-analysis. *Ophthalmology*. 2021 Nov 1;128(11):1580-91.

13. Basit A, Fawwad A, Baqa K. Pakistan and diabetes—A country on the edge. *Diabetes research and clinical practice*. 2019 Jan 1;147:166-8.
14. Jokhio AH, Talpur KI, Shujaat S, Talpur BR, Memon S. Prevalence of diabetic retinopathy in rural Pakistan: A population based cross-sectional study. *Indian Journal of Ophthalmology*. 2022 Dec;70(12):4364.
15. Im JH, Jin YP, Chow R, Yan P. Prevalence of diabetic macular edema based on optical coherence tomography in people with diabetes: A systematic review and meta-analysis. *Survey of Ophthalmology*. 2022 Jul 1;67(4):1244-51.
16. Lundeen EA, Andes LJ, Rein DB, Wittenborn JS, Erdem E, Gu Q, Saaddine J, Imperatore G, Chew EY. Trends in prevalence and treatment of diabetic macular edema and vision-threatening diabetic retinopathy among Medicare Part B Fee-for-Service beneficiaries. *JAMA ophthalmology*. 2022 Apr 1;140(4):345-53.
17. Sharma S, Karki P, Joshi SN, Parajuli S. Optical coherence tomography patterns of diabetic macular edema and treatment response to bevacizumab: a short-term study. *Therapeutic Advances in Ophthalmology*. 2022 Mar;14:25158414221074519.
18. Mitchell P, Sheidow TG, Farah ME, Mahmood S, Minnella AM, Eter N, Eldem B, Al-Dhibi H, Macfadden W, Parikh S, Dunger-Baldauf C. Effectiveness and safety of ranibizumab 0.5 mg in treatment-naïve patients with diabetic macular edema: Results from the real-world global LUMINOUS study. *PLoS One*. 2020 Jun 3;15(6):e0233595.
19. Yalamanchili SP, Maatouk CM, Enwere DU, Conti TF, Hom GL, Briskin IN, Greenlee TE, Babiuch AS, Singh RP. The short-term effect of a single lapse in anti-vascular endothelial growth factor treatment for diabetic macular edema within routine clinical practice. *American journal of ophthalmology*. 2020 Nov 1;219:215-21.
20. Olufemi O, Adekunle H, Idris O. A Comparison of Visual Outcomes Between Patients Treated with Intravitreal Ranibizumab and Bevacizumab for Diabetic Macula Edema in A Real World Setting in Sub-Saharan Africa. *Ophthalmol Res*. 2022;5(1):1-5.
21. Malik HA, Sabih R, Khan H, Asrar A, Asif M. Comparison of Intravitreal Bevacizumab versus Intravitreal Ranibizumab in Treatment Naive Macular Edema Patients (Real World Evidence in Pakistan): <http://doi.org/10.36351/pjo.v37i2.1194>. *Pakistan Journal of Ophthalmology*. 2021 Jan 30;37(2).
22. Mirshahi R, Falavarjani KG, Molaei S, Habibi A, Anvari P, Khorasani MA, Ghasemizadeh S, Sarraf D. Macular microvascular changes after intravitreal bevacizumab injection in diabetic macular edema. *Canadian Journal of Ophthalmology*. 2021 Feb 1;56(1):57-65.
23. Ataş M, Ozsaygılı C, Bayram N, Unal S. Retrospective analysis of the efficacy of early switching from bevacizumab to aflibercept or ranibizumab in diabetic macular edema. *European Journal of Ophthalmology*. 2023 Mar;33(2):1132-9.

Authors Contribution

Concept and Design: Rehan Saleem
 Data Collection / Assembly: Waseem Akhter
 Drafting: Salman Tariq Toosy, Fuad Khan Niazi
 Statistical expertise: Irum Yousafzai
 Critical Revision: Afia Matloob Rana